

# Role of Thyroxine in Minocycline Induced Hypothyroidism in Guinea Pigs

1. Naheed Gohar 2. Syed Meesam Iftkhar 3. Muhammad Farid Ullah

1. Sen. Lecturer of Anatomy, JM&DC, Karachi 2. Assoc. Prof. of Anatomy, JM&DC, Karachi 3. Asstt. Prof. of Anatomy, QAMC, Bahawalpur

## ABSTRACT

**Background:** Minocycline has been used for decades for the treatment of infections caused by a wide range of Gram negative and Gram positive organism. Minocycline has reported to cause hypothyroidism and goiterogenic affects which results in inhibition of thyroid hormones formation.

**Objective:** The thyroid gland is mostly affected by many drugs; these drugs include lithium, amiodarone, nitroprusside, perchlorate, sulfonyleurea, minocycline, phenylbutazone, and betadine. The long term use of these drugs is usually associated with hypothyroidism. So the present study was undertaken to observe the role of thyroxine in Minocycline induced thyroidal hormonal disturbance in Guinea pigs.

**Study Design:** Prospective experimental study

**Place and Duration of Study:** This study was conducted in the Department of Anatomy, Basic Medical Sciences Institute, Jinnah Postgraduate Medical Centre (JPMC), Karachi from 10.10.2010 to 10.11.2010.

**Materials and Methods:** 30 adult male Guinea pigs were taken from the animal house weighing between 450-650 Grams. The animals were divided into three groups A, B and C on the basis of treatment given. Group A received control diet, Group B received minocycline (0.02mg/g/day) and Group C received minocycline (0.02mg/g/day) with 0.5ug/g/day thyroxin tablet for 8 weeks at the end of which they were sacrificed, blood sample were taken for serum TSH, T3 and T4.

**Results:** There was highly significant decrease in body weight, increase in both absolute and relative weight of thyroid gland, marked increase in serum TSH, but the serum level of both T3 and T4 were found decreased in guinea Pigs receiving minocycline. Increase in body weight and decrease in both absolute and relative weight of thyroid gland, the level of TSH decreased, while serum levels of T3 and T4 increased in group C animals receiving minocycline with thyroxin.

**Conclusion:** This study was proved that use of thyroxin along with minocycline minimizes the harmful effects of minocycline on thyroid gland to a great extent and thyroxin was effective in preventing the hypothyroidism in experimental Guinea pigs.

**Key words:** Minocycline, thyroidal hormones, thyroxin, Guinea pigs.

## INTRODUCTION

The long term use of different drugs is usually associated with hypothyroidism (Vasudevn et al., 2011)<sup>1</sup>. The tetracyclines are drugs which remain drugs of first choice for infection with chlamydia, rickettsia (Q fever, typhus), vibrio cholera (cholera) and in acne (Bennett and Brown 2009)<sup>2</sup>. Minocycline is a semisynthetic broad spectrum antibacterial agent that was introduced in 1967 by the Erstwhile Le drele Laboratories (Eisen D & Hakim MD, 1998)<sup>3</sup>. The percentage of an oral dose that is absorbed with an empty stomach is high for Minocycline i.e. 100% (Brunten et al., 2009)<sup>4</sup>. The lipophilic properties of minocycline, with complete oral absorption and good sebum penetration, make it the most widely prescribed systemic antibiotic used to treat acne vulgaris, often given for months or years (Ramakrishna. et al., 2009)<sup>5</sup>. Minocycline with proven safety, which has been commonly used to treat pneumonia and acne as well as infections of the skin, genital and urinary systems, Central nervous system, gonorrhoea, meningitis, shigellosis, conjunctivitis, psittacosis, Q fever,

relapsing fever, and syphilis ( Elewa H. F et al., 2006)<sup>6</sup>. Minocycline has several immunomodulatory and neuroprotective properties independent of its antimicrobial functions (Skripuletz et al., 2010)<sup>7</sup>. The drug persists in the body long after its administration is stopped possibly due to retention in fatty tissues (Brunten et al., 2009)<sup>4</sup>. Minocycline is associated with hypothyroidism, predominantly with concurrent chronic lymphocytic thyroiditis (Tacon et al., 2008)<sup>8</sup>. Minocycline has goiterogenic effects with inhibitory effects on thyroid function resulting in inhibition of thyroid hormone formation. Iodination of thyroglobulin is inhibited by minocycline, which also strongly inhibits coupling of triiodothyronine (T3) and thyroxin (Taurog et al., 1996)<sup>9</sup>.

Thyroxin has an antioxidant activity in microsomal and mitochondrial fraction from liver and can prevent formation of free radicals in neutrophils (Golkin et al., 2001)<sup>10</sup>. Synthetic thyroxin is today the most commonly used drug for treating congenital hypothyroidism or post-operative thyroid cancer (Chao et al., 2009)<sup>11</sup>. Administration of L- thyroxin is a common medical treatment for nodular goiter (Fiore et

al., 2010)<sup>12</sup>. The general effect of thyroid hormone is to activate nuclear transcription of large numbers of genes. Therefore, in virtually all cells of the body, great number of protein enzymes, structural proteins, transport proteins and other substances are synthesized. The net result is generalized increase in functional activity throughout the body. The thyroid hormones increase the metabolic activities of almost all the tissues of the body. In adult, thyroid hormone helps to maintain brain function food metabolism and body temperature, among other effects (Saicic et al., 2006)<sup>13</sup>.

## MATERIALS AND METHODS

This study was conducted in the Department of Anatomy, Basic Medical Sciences Institute, Jinnah Postgraduate Medical Centre (JPMC), Karachi, for 8 weeks. This is a prospective experimental study.

Thirty (30) healthy and active adult male Guinea Pigs, weighing between 450-650 gm. were selected for the present study. The animals were divided into three groups A, B and C according to the treatment given to them.

In this study, minocycline was used, in the dose of 0.02mg/g/day and Tablet thyroxin was used in the dose of 0.5ug/g/day

**Group A:** This group comprised of 10 animals and they will serve as control. The animals were maintained on standard laboratory diet and water ad libitum.

**Group B:** This group comprised of 10 animals. The animals were given 0.02mg/g/day minocycline (Steifel Laboratories Pakistan (Pvt) Ltd, Steifel Laboratories Inc. Coral Gables, FL33134, and USA) orally.

**Group C:** This group comprised of 10 animals. The animals were given 0.5ug/g/day thyroxin tablet (GlaxoSmithKline Pakistan Ltd, RN 000374, MI 000017 & 000233) orally and minocycline (Steifel Laboratories Pakistan (Pvt) Ltd, Steifel Laboratories Inc. Coral Gables, FL33134, USA) orally.

Throughout the study period the animals were observed for their general health, activity and behaviour. Weight of the animals was done at the commencement of study and just before sacrifice.

After completion of study period (at the end of 8 weeks, the incision was made in neck region from chin to xiphisternum, infrahyoid muscles were retracted to expose the thyroid, and thoracic viscera were exposed by careful removal of skin, fascia and muscles to take blood sample by intra cardiac puncture and were kept in labeled tubes containing 10µl sodium EDTA, kept on ice until centrifuged. After centrifugation the plasma was aliquot and kept frozen at -70°C until assay. The thyroid function test (TSH, T3 and T4) was assessed by Total ELISA Kit from diagnostic systems laboratories. Thyroid glands were removed from the site and washed with normal saline.

The statistical significance of differences of various quantitative changes between treated and control rats were evaluated by the paired sample 't' test<sup>12</sup>. The numerical data was subjected to SPSS software for

statistical analysis. The difference was regarded as statistically significant if the P-value was equal to, or less than 0.05.

## RESULTS

**Relative weight of thyroid gland:** The mean values of relative weight of thyroid gland in control group A was  $10.3 \pm 0.23$  gm. A highly significant increase ( $p < 0.001$ ) was observed in group B when compared with the mean values of relative weight of thyroid gland in group A. There was moderately significant ( $P < 0.01$ ) decrease in relative weight of thyroid gland of group C when compared with group B, however a significant ( $p < 0.05$ ) difference was noted when compared with mean value in group A with C (Table-1 & figure: 1).

**Table No.1: Mean relative weight of thyroid gland in different groups of guinea pigs**

Groups	Treatment	Thyroid gland relative weight (mg/100gm body weight)
A	Normal diet (ND)	$10.3 \pm 0.23$
B	Minocycline	$25.9 \pm 1.47$
C	Minocycline + Thyroxin	$17.4 \pm 0.65$

\*Mean  $\pm$  SEM

### Statistical analysis of the mean relative weight of thyroid gland between different groups

Groups	P-value
A Vs B	$P < 0.001$ ****
B Vs C	$P < 0.01$ ***
A Vs C	$P < 0.05$ **

**Key: Insignificant\* Significant\*\* moderately significant\*\*\* highly significant\*\*\*\***

**Table No.2: Mean plasma levels of TSH, T3 and T4 in different groups of guinea pigs**

Groups	Serum TSH µl/ml	Serum T3 ng/dl	Serum T4 µg/dl
A	$0.2 \pm 0.01$	$4.9 \pm 0.31$	$34.5 \pm 2.34$
B	$6.5 \pm 0.26$	$2.3 \pm 0.15$	$15.5 \pm 1.23$
C	$0.7 \pm 0.05$	$4.1 \pm 0.28$	$29.3 \pm 1.57$

### Statistical analysis of the mean plasma TSH, T3 and T4 levels in different groups of guinea pigs

Groups	Serum TSH	Serum T3	Serum T4
A Vs B	$P < 0.001$ ****	$P < 0.001$ ****	$P < 0.001$ ****
B Vs C	$P < 0.01$ ***	$P < 0.01$ ***	$P < 0.01$ ***
A Vs C	$P < 0.05$ **	$P < 0.05$ **	$P < 0.05$ **

**Key: Insignificant\* Significant\*\* moderately significant\*\*\* highly significant\*\*\*\***

**Hormonal assay:** The mean values of plasma TSH in group A was  $0.2 \pm 0.01$  µl/ml. The increase in hormone level in group B was highly significant ( $P < 0.001$ ) when compared with group A and there was a moderately significant ( $p < 0.01$ ) decrease in group C when compared with the group B. The mean value of TSH is

increased significantly ( $p < 0.05$ ) when compared with group C with group A (Table-2 and figure: 2). Plasma tri-iodothyronine (T3) levels were estimated in all animals. The decrease in hormone levels in group B was highly significant ( $p < 0.001$ ) when compared with group A and there was moderately significant ( $p < 0.01$ ) increase in group C when compared with group B. The mean value of T3 in group C was decreased significantly ( $P < 0.05$ ) when compared with group A. (Table-2 and figure: 3).

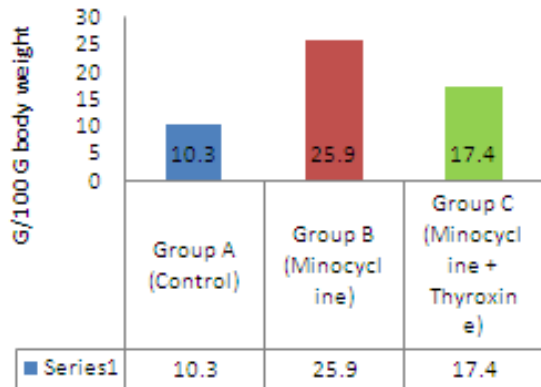


Figure No.1: Mean Relative Weight of Thyroid gland

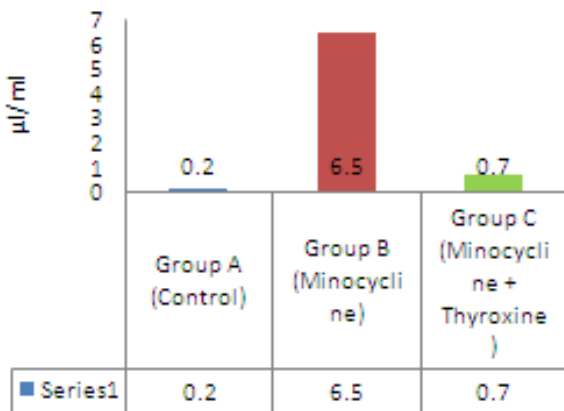


Figure No.2: Mean Plasma Level of TSH

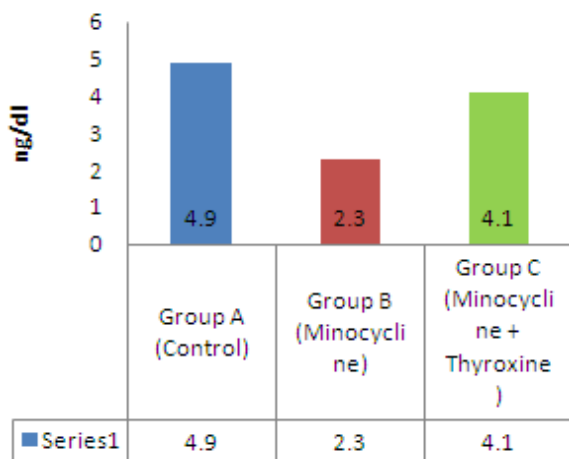


Figure No.3: Mean Plasma Level of T3.

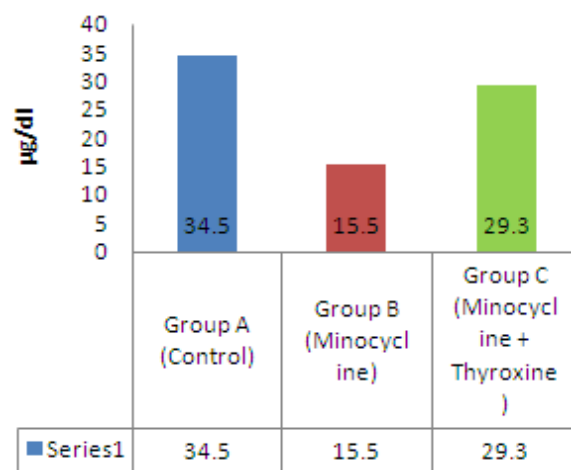


Figure No.4: Mean Plasma Level of T4.

Plasma T4 (Thyroxin) levels were estimated in all animals. The decrease in hormone levels in group B was highly significant ( $p < 0.001$ ) when compared with group A and there was a moderately significant decrease in B when compared with group C. The mean value of plasma T4 level was significantly ( $p < 0.05$ ) decreased in group C when compared with group A (Table-2 and figure: 4).

## DISCUSSION

The present study was carried out by observing and recording the effects of minocycline on the relative weight of thyroid gland and estimation of hormonal levels (TSH, T3 and T4). Numerous studies on minocycline have shown that it possesses potent antithyroid effects probably by inhibiting the iodination of thyroglobulin and also by inhibiting the coupling of diiodotyrosine residues to form triiodothyronine and thyroxine (Bowles et al., 1998)<sup>14</sup>. Understanding the mechanism of action of antithyroid effects is important in elucidating not only the cause of hypothyroidism in human being exposed to solve this problem but also its prevention.

Relative weight of thyroid glands was highly significant increase in group B animals. The increase in weight could be due to hypertrophy of follicular cells and deposition of melanin pigment inside the follicular cells and within the colloid. Inuwa and William (1995)<sup>15</sup> suggested that, it might be due to the increased follicular epithelial height (from basement membrane to surface) in hypothyroid rats, he observed that the epithelial height in hypothyroid rats given thyroxine was not significantly increased when compared with euthyroid rats.

In minocycline and thyroxin treated group C animals, the relative weight of the thyroid gland was decreased when compared to minocycline treated group B animals; it might be due to decreased cellular hypertrophy and less inflammatory changes. This is in agreement with Joffe et al (2007)<sup>16</sup> who proved that in

the presence of thyroxine the height of cells of follicles comes to near in height of follicular cell of control group and colloid was again restored in the lumen of follicles.

There was highly significant increase in serum TSH (thyroid stimulating hormone) hormonal level in minocycline treated group B animals. In ultra-structural study of black thyroids, Taurog et al (1996)<sup>9</sup> reported that patient taking minocycline presented with clinical and laboratory evidence of thyroid hypo function (decreased serum T4 and increased serum TSH). Capen (1997)<sup>17</sup> observed that the lowers circulating T3 levels, which results in a compensatory increased secretion of thyroid stimulating hormone (TSH), follicular cells hypertrophy and hyperplasia.

There was significant increase in levels of both T3 and T4 hormones and significant decrease of TSH hormone in group C animals. Suppression of serum TSH concentration by administering exogenous thyroid hormone may interfere with the growth of established nodules as well as with the formation of new thyroid nodules (Fiore E et al, 2010)<sup>12</sup>. Chao et al (2009)<sup>11</sup> stated that the treatment with thyroxine (T4) is probably safer than treatment with a combination of T4 and T3. Therefore, T4 alone contuse to be the most appropriate therapy for patients with hypothyroidism. Carroza et al (1999)<sup>18</sup> has proved that the most of T3 is derived from thyroxine.

## CONCLUSION

The present study shows development of hypothyroidism as a result of administration of minocycline. The study further emphasizes a definite preventive role of thyroxine on minocycline induced hypothyroidism in case of long term use of minocycline.

## REFERENCES

1. Vasudevn DM, Sreekumari S, Vaidyanathan. Thyroid hormones. In: Text book of Biochemistry for medical students. 6<sup>th</sup> ed. New Delhi: Jaypee Brothers Medical Publishers; 2011. p. 538.
2. Bennet PN, Brown MJ.. Antibacterial drugs. Clinical pharmacology. 9<sup>th</sup> ed. United Kingdom: Elsevier; 2005.p. 215-235.
3. Eisen D, Hakim MD. Minocycline induced pigmentation, incidence, prevention and management. *Pharmacoepidemiology drug safety* 1998;18 (6):431-440.
4. Brunten LL, Lazo JS, Parku KL. Protein synthesis inhibitors and miscellaneous antibacterial agents. Goodman and Gilman's Pharmacological basis of therapeutics. 11<sup>th</sup> ed. 2006.p. 1173-1176.
5. Ramakrishna J, Johnson MD, Banner. Long term minocycline use for acne in healthy adolescents can cause severe Autoimmune Hepatitis. *J Clin Gastroenterol* 2009; 43(8) 787-790.

6. Elewa HF, Hilali H, Hess DC, Machado LS, Fagan SC. Minocycline for short- term neuroprotection. *Pharmacotherapy* 2006; 26(4) 515-521.
7. Skripuletz T, Miller E, Khiabani DM. Beneficial effects of minocycline on cuprizone induced cortical demyelination. *Neurochemical research* 2010; 35: 1422-1433.
8. Tacon L, Tan CTK, Alvarado R, Gill AJ, Sywak M, Fulcher G. Drug induced thyroiditis and papillary carcinoma in a Minocycline –Pigmented Black Thyroid Gland. *Thyroid* 2008;18(7): 795-797.
9. Taurog A, Dorris ML, Doerge DR. Minocycline and thyroid: Antithyroid effects of the drugs, and the role of thyroid peroxidase in minocycline induced Black pigmentation of the gland. *Thyroid* 1996; 6(3): 211-219.
10. Galkina OV, Prokopenko VM, Eshchenko ND, Arutyunyan AV. The effects of thyroxine Isomers on free radical oxidation processes in subcellular fractions of Rat Cerebral cortex. *Neuroscience and behavioral physiology* 2001; 31(4): 463-465.
11. Chao M, Jiawei X, Xia H, Guoming W, Yangang W, Xufu W, et al. Thyroxine alone or thyroxine plus triiodothyronine therapy for hypothyroidism. *Nuclear medicine communications* 2009;30(8): 586-593.
12. Fiore E, Rago T, Provenzale MA, Scutari M, Ugolini C, Basolo F, et al. L- thyroxine treated patient with nodular goiter have lower serum TSH and lower frequency of papillary thyroid cancer: results of a cross-sectional study on 27914 patients. *Endocrine related cancer* 2010;17: 231-239.
13. Saicic ZS, Mijalkovic DN, Nikolic AL, Blagojevic DP, Spasic MB. Effects of thyroxine on antioxidant defense system in the Liver of Rats of different age. *Physiological research* 2006; 55: 561-568.
14. Bowles WH. Protection against minocycline pigment formation by ascorbic acid (vitamin C). *J Esthetic Dentistry* 1998;10(4):182-186.
15. Inuwa I, Williams MA. Morphometric study on the uterine horn and thyroid gland in hypothyroid, and thyroxine treated hypothyroid rats. *J Anatomy* 1996; 188: 383-393.
16. Joffe RT, Brimacombe M, Levitt AJ, Stagnaro-Green A. Treatment of clinical hypothyroidism with thyroxine and triiodothyronine. *Psychosomatic* 2007;48:379-384.
17. Capen CC. Mechanist data and risk assessment of selected toxic end point of the thyroid gland. *Toxicological pathology* 1997; 25(1): 39-48.
18. Carroza V, Csako G, Yanovski JA, Sharulis MC, Nieman L, Wesley R, et al. Levothyroxine replacement therapy in central hypothyroidism. *Pharmacotherapy* 1999; 19(3): 349-355.

**Address for Corresponding Author:**

**Dr. Naheed Gohar Cell No.03012476964**