

Early Response of the Ponseti Method for the Treatment of Idiopathic Congenital Clubfoot

1. Zahoor I. Soomro 2. Karam A. Shah 3. Saeed A. Shah 4. Zulfiqar A. Mastoi

1. Sr. Registrar Orthopaedic Surgery 2. Asstt. Prof. of Orthopaedic Surgery 3. Asstt. Prof. of Orthopaedic Surgery
4. Prof. of Orthopaedic Surgery, Peoples University of Medical & Health Sciences Nawabshah

ABSTRACT

Objective: The objective of this study is to assess the early response of the Ponseti method for the treatment of idiopathic congenital clubfoot by using the Pirani scoring system.

Study Design: Prospective study.

Place and Duration of Study: At the Department of Orthopaedic Surgery Peoples University of Medical & Health Sciences (PUMHS) Nawabshah from JAN 2011 to DEC 2011 (ONE YEAR).

Materials and Methods: Total numbers of 50 cases with 79 feet of idiopathic congenital clubfoot up to the age of one year of either sex were included in this study.

Results: The correction was obtained in 47 (94%) cases but three infants required Posteromedial release (PMR) operation. Average number of casts applied was 5.7 (range: 4-8), average time for full correction was 10 weeks (range: 4-12 weeks), percutaneous Achilles tenotomy was required in 84% of cases. Mean comparison of Pirani score was significantly decreased at final stage.

Conclusion: The Ponseti method is a safe and effective treatment, that PMR surgery is no longer necessary for the majority of idiopathic congenital clubfeet.

Key Words: Idiopathic, Clubfoot, Ponseti

INTRODUCTION

Idiopathic congenital clubfoot or talipes equinovarus (CTEV) is a complex deformity occurring in an otherwise normal child since birth¹. Exact etiology is unknown, however various theories include primary germ plasm defect, intrauterine malposition, and genetic disorder have been suggested. Incidence is one per 1000 livebirths², boys are affected twice than girls, >50% of cases are bilateral while right sided preponderance in unilateral cases³. Deformity consists of 4 components: hindfoot equinus, hindfoot varus, forefoot adductus, and cavus.

The goal of treatment is to correct all components of deformity with a pain free, plantigrade foot with good mobility, therefore most orthopaedists have agreed that the initial treatment should be non.surgical, most of them involving manipulation and casting for many months which often resulted in partial correction⁴. The partially corrected feet were then treated by posteromedial release operations. The long term results have been disappointing include wound infection, wound dehiscence, overcorrection, heel valgus, undercorrection, heel varus, persistant equinus, metatarsus adductus, stiffness, and weakness leading to premature arthritis⁵.

Because of these complications a renewed interest in conservative treatment in the form of Ponseti has occurred⁶. Since the late 1940s, Ignacio V. Ponseti, MD at university of Iowa, developed a method of clubfoot correction which is easy to learn and has been recommended for use in developing world with a high

success rate of 83-98%⁷⁻⁹. With increased understanding of the biology of the deformity and of the functional anatomy of the clubfoot, the Ponseti technique has developed to give, in most cases, a result superior to that achieved by surgery¹⁰. Therefore Ponseti described a study on histological section of ligaments from clubfeet, revealed that the abundant young collagen in the ligaments was very wavy, was very cellular known as crimp. This crimp allows the ligaments to be stretched. The crimp reappears a few days later, allowing for further stretching. That is why manual correction of the deformity is feasible. Also he described that there is no single axis of motion exists on which to rotate the tarsus. The tarsal joints are functionally interdependent. The movement of each tarsal bone involves simultaneous shifts in the adjacent bones¹¹.

This method involves weekly stretching of the deformity followed by application of a long leg cast. All components of deformity usually correct within 5 to 6 weeks, with the exception of the equinus. A simple percutaneous Achilles tenotomy is often necessary to complete the correction. After correction a foot-abduction brace is used to maintain the correction¹². This technique results in strong, flexible and plantigrade feet with maintenance of function without pain has been demonstrated in a 35-years follow-up study¹³.

The purpose of this study is to assess the early response of the Ponseti method for the treatment of idiopathic congenital clubfeet by using the Pirani severity scoring system.

MATERIALS AND METHODS

The study has been conducted from Jan 2011 to Dec 2011 at the Department of Orthopaedic Surgery Peoples University of Medical & Health Sciences (PUMHS) Nawabshah. Fifty cases with 79 feet of either sex up to the age of one year were included in the study. Clubfoot deformity secondary to Polio, Cerebral Palsy, Arthrogyrosis, and Meningomyelocele were excluded from the study⁸. Infants were evaluated and graded for severity by using the Pirani scoring system, which is based on physical examination and require no radiographic measurements or other special studies¹³. It comprises six clinical signs of contracture, each is scored according to the following principle: 0, no abnormality; 0.5, moderate abnormality; 1, severe abnormality. The six signs are separated into three related to the hindfoot (severity of posterior crease, emptiness of the heel, and rigidity of the equinus), and three related to the midfoot (severity of medial crease, curvature of lateral border of foot, and position of lateral part of the head of the talus). Thus, each foot can receive a hindfoot score between 0 & 3, a midfoot score between 0 & 3, and a total score between 0 & 6^{9,14,15}.

Treatment Protocol (FIG: 1): The course of treatment followed the principles of manipulation and casting described by Ponseti as follows:

1. All components of the deformity are corrected simultaneously, not in sequence, except for the equinus, which should be corrected last.
2. The cavus, which results from pronation of the forefoot in relation to the hindfoot, is corrected together with the adduction by supinating and abducting the forefoot in proper alignment with the hindfoot.
3. With the longitudinal arch of the foot well molded and the forefoot in some supination, the entire foot can be gently and gradually abducted under the talus, which is secured against rotation in the ankle mortise by applying counter pressure with the thumb against the lateral part of the head of the talus.
4. Heel varus will correct when the entire foot is fully abducted under the talus. The heel is never touched.
5. Finally, the equinus is corrected by dorsiflexing the foot. This is generally facilitated by a simple percutaneous Achilles tenotomy under local anaesthesia.

To maintain the correction obtained by gentle manipulation, a plaster cast is applied in two sections. The first section extends from the toes to just below the knee and the second covers the knee and thigh. The knee is immobilized at a right angle. The plaster cast is molded to fit the anatomy precisely. Abduction of the foot is progressively increased with each manipulation

and plaster cast application until hypercorrection to about 70 degrees of foot abduction is obtained^{7,11,12,16,17}. A foot-abduction brace is used to maintain the correction. This brace consists of a bar with shoes attached at the ends at 70 degrees of outward rotation on the affected side and 40 degrees on the normal side. The length of the bar should be equal to the width of the child's shoulders. The brace is used on a full-time basis for 2 to 3 months, and at night and during naptime for 3 to 4 years^{11,18}.

Analysis: The early response of the Ponseti method has been measured in terms of age of the patients, initial severity score of the deformity, total number of casts applied, time required for full correction of the deformity, and final severity score of the deformity.

RESULTS

Total number of 50 cases of either sex with idiopathic congenital clubfoot deformity up to the age of one year were included in this study. Out of 50 infants 34 (68 %) were male and 16 (32 %) were female with M:F = 2.1:1. Age range was 0.5-12 months, with maximum number of infants 33 (66 %) were lying between 2 weeks to 4 months. The earliest cast applied was at an age of 5 days, and the maximum age at which a cast applied was at 11 months. Out of 50 cases, 29 (58 %) of clubfeet were bilateral; while 13 (26 %) cases were right sided and 8 (16 %) of clubfeet were left sided.

Distribution of Pirani's initial severity score of right foot, score range was 3.5-6 and maximum number of patients had score 5 while mean (\pm SD) score was 4.9 (\pm 0.6). Distribution of Pirani's initial severity score of left foot, score range was 3.5 - 5.5 and maximum number of patients had score 5 and 5.5 while mean (\pm SD) score was 4.8 (\pm 0.65). Percutaneous Achilles tenotomy was done in 42 (84 %) cases.

Distribution of casts applied is presented in fig. 2, the number of casts range was 4 - 8 and mean (\pm SD) number of casts was 5.74 (\pm 1.12). Time (in weeks) for full correction of deformity is presented in fig. 3. Full correction occurred in 4-12 weeks, in 26 (52 %) cases correction was achieved in 10 weeks; mean (\pm SD) was 8.5 (\pm 2.0) weeks.

Distribution of Pirani's final severity score of right foot, score range was 0-3 and maximum number of patients had score 1 while mean (\pm SD) score was 0.833 (\pm 0.928).

Distribution of Pirani's final severity score of left foot, score range was 0-2.5, and maximum number of patients had scored 0.5 while mean (\pm SD) score was 0.581 (\pm 0.692).

Mean comparison of Pirani's score at initial and final stages is presented in table I. Mean scores of both right and left foot was significantly decrease at final stage as compared with initial Pirani's score (both p-values < .0001).

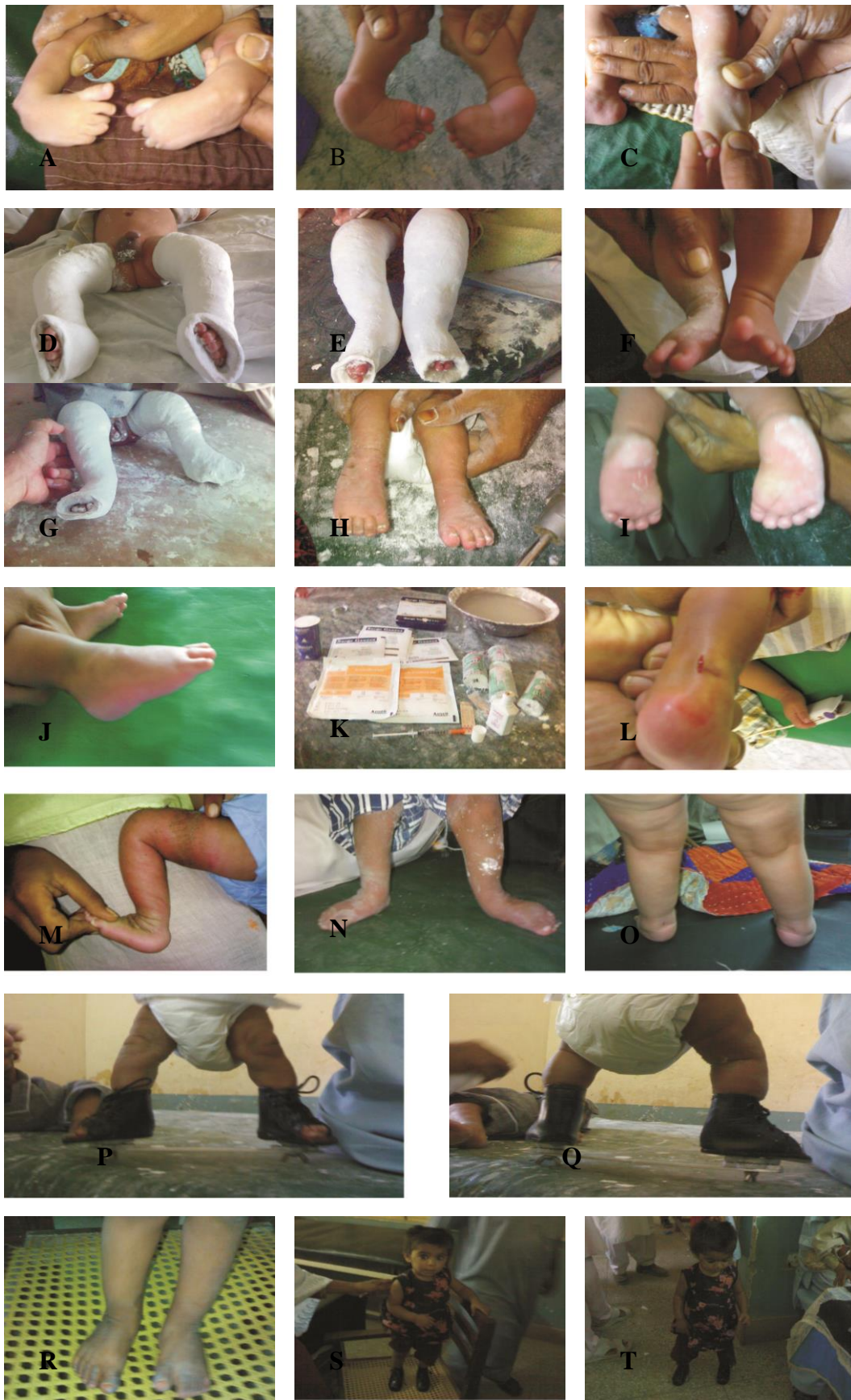

Fig No. 1: Summary of ponseti method from manipulation, serial casting, p/c tenotomy to bracing program

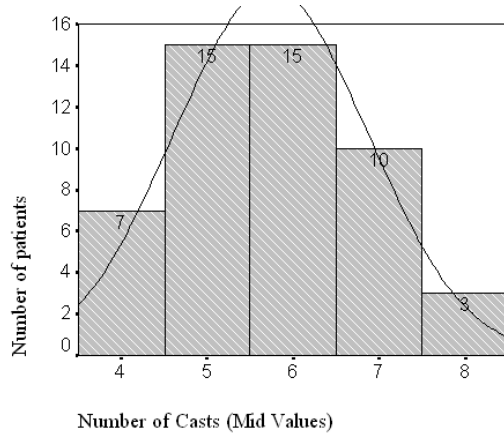
Table No.1: Mean Comparison of Pirant's Score at Initial and Final Stages n=50

Slides	Pirani's Severity Score		P-Values*
	Initial Mean ± SD	Final Mean ± SD	
Right	4.952±0.623	0.833±0.928	< .0001**
Left	4.797±0.65	0.581±0.692	< .0001

*By using student-t test

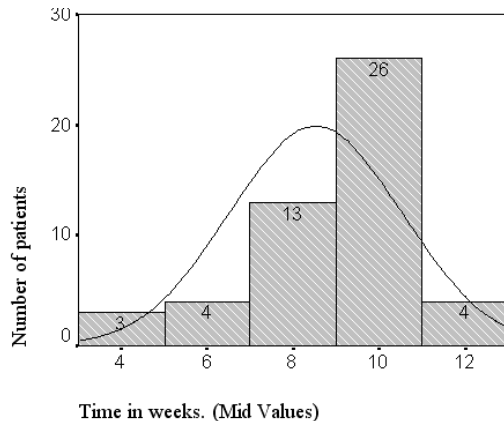
**Difference was significant

Key: SD=Standard Deviation



Rang = 4 – 8
Mean± SD = 5.74± 1.12

Figure No.2: Distribution of total number of casts applied.



Rang = 4 – 12
Mean± SD = 8.5± 2.0

Figure No. 3: Time required for full correction of deformity.

DISCUSSION

In published series success is defined as treatment that avoids a surgical soft tissues release operation and thus in this study the success rate is 94% (47 cases), a figure that compares with other series i.e, 83-98%. The results obtained in this study are comparable to those mentioned in the international literature^{6-9,12,16,19}.

In this study, the Pirani's initial severity score was 3.5-6 and maximum number of patients had score 5, this is comparable with the study of Grag et al; and revealed

that most of the patients presented had severe deformity⁹. The number of casts per feet in this study was 4-8 (average: 5.7). In a series by Ponseti et al; it was 5-10 (average: 7.6), by Laaveg et al; it was 7, by Mourcuende et al; the number was 5. Clubfeet presenting with a Pirani score of > 5 require more cast changes^{15,20}. In this study, the time for full correction of deformity required 4-12 weeks (average: 8.5 weeks).Ponseti et al; required 5-12 weeks, Laaveg et al; required 8.6 weeks, and Mourcuende et al; reported 7 weeks.

In this study, percutaneous Achilles tenotomy was needed in 84% Of cases. In a series by Pirani et al; he did tenotomy in 90%, Dobbs et al; in 91%, Laaveg et al; in 78%, and Changulani et al; experienced tenotomy in 85% of cases^{17,21}. I agreed with the findings of Scher et al; that clubfeet with Pirani score of > 5 are highly likely to need an Achilles tenotomy²². These final results showed the mean scores of clubfeet were significantly decreased at final stage as compared with the initial Pirani's score (p-values < .0001).

On the contrary to other published studies, that the deformity can be corrected up to the age of 2 years²³. In this study we found difficulty in correcting the deformity in children older than 9 months. Three of our patients treated with Ponseti method required PMR operation, and this was attributed to the late presentation of infants with severe Pirani score of 6. We observed that these older patients were difficult to hold in proper position and also difficult to do tenotomy under local anaesthesia. Therefore we experienced that these infants should undergo general anaesthesia for proper manipulation, tenotomy and casting.

Recent publications have stressed the importance of compliance with bracing program. Since most of the patients in the current study are from the lower class, educational level is low and thus they fail to understand the importance of bracing to maintain the correction. Strict instruction for the brace application, motivation by dedicated personnel, peer comparison and more frequent follow-up have lead to increased compliance. Mourcuende et al; described a relapse rate of > 80% in non.compliant cases. This is in contrast to a relapse rate of only 6% in compliant families^{13,24}.

In this series, the initial experience with the use of Ponseti method at PUMHS Nawabshah is as good as those from other published series. This study needs a future follow-up of these infants up to the age of skeletal maturity to observe the long-term effects of early response with Ponseti method. Lastly, the Ponseti method has been recommended for use in the developing world due to its simplicity, high success rate, and low demands on health resources²⁵.

CONCLUSION

The Ponseti technique is a safe, easy, result-oriented, economical, and effective method of treatment, that posteromedial release operation is no longer necessary for the majority of idiopathic congenital clubfeet.

REFERENCES

1. Ponseti IV, Zhivkov M, Davis N, Sinclair M, Dobbs MB, Mourcuende JA. Treatment of the complex idiopathic clubfoot. *Clin Orthopaedics and Related Research* 2006; 451: 171-6.
2. Skinner HB, Rab GT. Congenital clubfoot. Current diagnosis and treatment in orthopaedics. 4th ed. New York. Chicago. London. Sydney. Toronto: McGraw-Hill Co; 2006. 613-5.
3. Shah RA. Clubfoot in children surgical/ operative treatment. *Ann. Abbasi Shaheed Hosp. Karachi & KMDC Coll* 2004; 9 (2): 605-7.
4. Sud A, Tiwari A, Sharma D, Kapoor S. Ponseti's vs Kite's method in the treatment of clubfoot- a prospective randomized study. *Int Orthop* 2007; 24: [E pub ahead of print].
5. Dobbs M, Nunly R, Schoenecker PL. Long-term follow-up of patients with clubfeet treated with extensive soft tissues release. *J Bone Joint Surg* 2006; 88: 986-96.
6. Halanski MA, Davison JE, Huang JC, Walker CG, Walsh SG, Crawford HA. Ponseti method compared with surgical treatment of clubfoot: a prospective comparison. *J Bone Joint Surg* 2010; 92 (2): 270-8.
7. Zwick EB, Kraus T, Maizen C, Steinwender G, Linhart WE. Comparison of Ponseti versus surgical treatment for idiopathic clubfoot: a short-term preliminary report. *Clin Orthop Relat Res* 2009; 467 (10): 2668-76.
8. Din SU, Shah SA, Hayat S. Conservative treatment of congenital talipes equinovarus. *J Postgrad Inst* 2004; 18 (3): 368-72.
9. Changulani M, Grag NK, Rajagopal TS, Bass A, Nayagam SN, Sampath J, et al. Treatment of idiopathic clubfoot using the Ponseti method. Initial experience. *J Bone Joint Surg* 2006; 88-B: 1385-7.
10. Goksan SB, Bursali A, Bilgili F, Sivacioglu S, Ayanoglu S. Ponseti technique for the correction of idiopathic clubfeet presenting upto 1 year of age: a preliminary study in children with untreated or complex deformities. *Arch Orthop Trauma Surg* 2006; 126: 15-21.
11. Scher DM. The Ponseti method for clubfoot correction. *Oper Tech Orthop* 2005; 15: 345-9.
12. Bor N, Coplan JA, Herzenberg JE. Ponseti treatment for idiopathic clubfoot: minimum 5 year followup. *Clin Orthop Relat Res* 2009; 467 (57): 1263-70.
13. Ponseti IV, Mourcuende JA, Mosca V, Pirani S, Dietz F, Herzenberg JE, et al. In: Staheli L, editor. *Clubfoot: Ponseti management*. 3rd ed. Global-HELP; 2009.
14. Hussain FN. The role of the Pirani scoring system in the management of clubfoot by the Ponseti method. *J Bone Joint Surg* 2007; 89 (4): 561-2.
15. Dyer PJ, Davis N. The role of the Pirani scoring system in the management of clubfoot by the Ponseti method. *J Bone Joint Surg* 2006; 88 (8): 1082-4.
16. Porcha MM, Parmar DS, Chavda HR. Mid-term results of Ponseti method for the treatment of congenital idiopathic clubfoot- (A study of 67 clubfeet with mean 5 year followup). *J Orthop Surg Res* 2011 Jan; 6: 3.
17. Maranhão DA, Noqueira MH, Simão MN, Volpon JB. Ultrasonographic evaluation of Achilles tendon repair after percutaneous sectioning for the correction of congenital clubfoot residual equinus. *J Pediatr Orthop* 2009; 29 (7): 804-10.
18. Zions LE, Dietz FR. Bracing following correction of idiopathic clubfoot using the Ponseti method. *J Am Acad Orthop Surg* 2010; 18 (8): 486-93.
19. Zions LE, Zhao G, Hitchcock K, Maewal J, Ebramzadeh E. Has the rate of extensive surgery to treat idiopathic clubfoot declined in the united states? *J Bone Joint Surg* 2010; 92 (4): 882-9.
20. Mourcuende JA, Terrazas G. Effect of cast removal timing in the correction of idiopathic clubfoot by the Ponseti method. *Iowa Orthop J* 2007; 27: 24-7.
21. Bor N, Katz Y, Vofsi O, Herzenberg JE, Zuckerberg AL. Sedation protocols for Ponseti clubfoot Achilles tenotomy. *J Child Orthop* 2007; 1 (6): 333-5.
22. Scher DM, Feldman DS, Bosse HJP, Sala DA, Lehman WB. Predicting the need for tenotomy in the Ponseti method for correction of clubfoot. *J Pediatr Orthop* 2004; 24 (4): 349-52.
23. Haqazy M, Nasef NM, Abdel-Ghani H. Results of treatment of idiopathic clubfoot in older infants using the Ponseti method: a preliminary report. *J Pediatr Orthop* 2009; 18 (2): 76-8.
24. Haft GF, Walker CG, Crawford HA. Early clubfoot recurrence after use of the Ponseti method in a New Zealand population. *J Bone Joint Surg* 2007; 89 (3): 487-93.
25. Gupta A, Singh S, Patel P, Patel J, Varshney MK. Evaluation of the utility of the Ponseti method of correction of clubfoot deformity in a developing nation. *Int Orthop* 2008; 32 (1): 75-9.

Address for Corresponding Author:**Dr. Zahoor Illahi Soomro,**

Senior Registrar Orthopaedic Surgery,

PUM&HS, Nawabshah.

Email: zisoomro786@yahoo.com

Cell # 0301-3814247.

Mailing Address: H. No. A/134

G.E.C. Housing Society Nawabshah Sindh