

# Analyzing Genetic Influences on Facial Morphology Differences in Monozygotic Twins: A Retrospective Stereophotogrammetric Study

Genetic and  
Environmental  
Factors  
Influencing  
Facial  
Development

Sara mannan<sup>1</sup>, Gulmina Saeed Orakzai<sup>2</sup>, Waqar-Un-Nisa<sup>2</sup>, Misbah Ali<sup>3</sup>, Sobia Siddique<sup>2</sup>  
and Nauman Bari Khan<sup>3</sup>

## ABSTRACT

**Objective:** This retrospective study aimed to quantitatively assess soft tissue differences in facial morphology among monozygotic (MZ) twins using 3D stereophotogrammetry and surface-based analysis, aiming to provide insights into the interplay between genetic and environmental factors influencing facial development.

**Study Design:**

**Place and Duration of Study:** This study was conducted at the Department of Anatomy, Wateen Dental College, Rawalpindi from June 2022 to June 2023.

**Methods:** Twenty pairs of identical twins (8 males, 12 females) with an average age of  $5 \pm 1$  year were included in the study. 3D stereophotogrammetry images were obtained and analyzed using the 3dMDface system. Soft tissue differences were quantified using surface-based analysis, dividing the face into anatomical thirds.

**Results:** The study demonstrated a high degree of agreement in measurements, with an intraclass correlation coefficient ranging from 0.907 to 0.995. Soft tissue differences within MZ twin pairs were quantified, revealing mean deviations and RMS values across the total face and facial thirds. Significant differences were observed between the upper and lower facial thirds, indicating varied genetic and environmental influences.

**Conclusion:** The study highlights the complex interaction between genetic predispositions and environmental factors in shaping facial morphology. Surface-based analysis using 3D stereophotogrammetry provides detailed insights into facial resemblance within twin pairs, emphasizing the importance of personalized treatment plans tailored to individual needs. Further research is needed to elucidate the intricacies of facial development and diversity.

**Key Words:** Monozygotic twins, facial morphology, 3D stereophotogrammetry.

**Citation of article:** Mannan S, Orakzai GS, Waqar-Un-Nisa, Ali M, Siddique S, Khan NB. Analyzing Genetic Influences on Facial Morphology Differences in Monozygotic Twins: A Retrospective Stereophotogrammetric Study. Med Forum 2024;35(3):79-82.doi:10.60110/medforum.350318.

## INTRODUCTION

The importance of facial shape and attractiveness in the personal and professional realms is greatly emphasized in the modern period. As a result, the capacity to affect facial shape and development has attracted growing attention and significance. The development of the craniofacial region is a complex process that is impacted by both environmental variables later in life

and genetic and cellular processes during embryonic stages.<sup>1</sup> Therefore, the modulation of these elements is critical to the effectiveness of changing the morphology of the face through orthodontic or orthopedic procedures. Understanding the interaction between genetic predispositions and the effects of the environment on facial development has been made possible via research, including twin and family studies. Monozygotic twin studies, which take into account aspects including hormones, diet, trauma, illnesses, habits, and dental activities, have yielded important insights into these relationships.<sup>2</sup> These twins do not necessarily share environmental exposures, but they do share genetic features.

Because face features are complex, two-dimensional (2D) imaging methods have traditionally been used in research evaluating facial morphology.<sup>3</sup> While these approaches are valuable, they frequently miss important details. Facial morphology analysis has been transformed by advances in three-dimensional (3D) imaging technologies, such as cone-beam computed tomography, laser scanners, and 3D

<sup>1</sup>. Department of Anatomy / Oral Pathology<sup>2</sup>, Watim Dental College, Rawalpindi.

<sup>3</sup>. Department of Oral Pathology, Margalla Institute of Health Sciences, Rawalpindi.

Correspondence: Nauman Bari Khan, Associate Professor Margalla Institute of Health Sciences, Rawalpindi.  
Contact No: 0300-9562903  
Email: nauman@gmail.com

Received: July, 2023

Accepted: September, 2023

Printed: March, 2024

stereophotogrammetry, which provide more precise and thorough evaluations. Comparisons within 3D imaging techniques might be surface-based or landmark-based.<sup>4</sup> Surface-based comparisons are preferred because they may evaluate deviations throughout the entire face in three dimensions, instead of just concentrating on particular points, which is advantageous given the intricacy of facial features.<sup>5</sup>

Only a small number of studies investigating the morphology of the face in monozygotic twins have used surface-based comparisons, with most using landmark-based comparisons. These studies have brought attention to the effects of heredity on particular facial regions, including the protrusion of the upper lip and the midface. Surface-based analysis have highlighted the individuality of each person's facial characteristics by revealing quantifiable differences between twin pairs.<sup>6</sup> Variations in facial regions across monozygotic twins highlight the importance of environmental factors even when they have similar genetic makeup. This emphasizes how important it is to use personalized treatment plans that are suited to the particular needs of every patient, including identical twins. The current work set out to examine discrepancies in different facial regions using 3D stereophotogrammetry, as well as to quantitatively measure soft tissue variations across monozygotic twin pairs over the entire face.

## METHODS

The data for the retrospective study came from the records of the study was conducted at the Department of Anatomy, Wateen Dental College, Rawalpindi, and included twenty pairs of identical twins, 8 boys and 12 females, with an average age of  $5 \pm 1$  year, drawn from June 2022 to June 2023. For this study, we looked for participants who met the following criteria: (1) good dental and skeletal alignment (Class I or mild Class II), (2) no previous orthodontic interventions, (3) no record of facial trauma or surgeries, (4) no craniofacial syndromes diagnosed, and (5) high-quality 3D stereophotogrammetry images not showing orthodontic treatments. Prior genetic testing for unrelated investigations confirmed zygosity.

**Data Collection and Measurements:** By combining the 3D stereophotogrammetric images with the 3dMDface, comparing the twins' soft tissues became a breeze. The six cameras, which can shoot simultaneously from varying angles and distances, are housed in two separate modular components. For the sake of uniformity, each participant sat on a height-adjustable chair and looked into a mirror mounted on the wall to see their head posture. Calibration of the system was required before the taking of each picture. First, we cropped the images by removing the areas around the ears, hair, and neck using the 3dMDvultus version 2.1 program developed by 3dMD Inc. After

that, we approximated the twin pairs' 3D pictures using global registration.

Once the 3D files were converted to the stereolithography format, they were then imported into the 3-matic program. Within the program, the twin pairs' approximated 3D images underwent further superimposition using the best-fit algorithm, which is based on the iterative closest point method. Dividing the face into thirds allowed us to draw separate lines for the upper lip and the lower lip and chin. By comparing segmented and superimposed regions, the software's "part comparison" capability enabled 3D deviation assessments.

For 95th percentile meshes, the histogram generated an RMS value and a colour map automatically; the colour map also supplied the mean deviation. Achieved automatically by the programme, the root-mean-square (RMS) value is the result of squaring the sum of all values. Results were given with median values and the interquartile range (Q1, indicating the 25th percentile and Q3, representing the 75th percentile, respectively), and the same author oversaw data preparation, measurement, and analysis.

## RESULTS

At 10-day intervals, the same researcher independently repeated all measurements. A high degree of agreement was shown by the intraclass correlation coefficient, which varied from 0.907 to 0.995 and is used to determine intraexaminer reliability.

**Table No. 1: Descriptive statistics for soft tissue differences within MZ twin pairs for the total face.**

| Measurement                  | Mean $\pm$ SD  |
|------------------------------|--|
| Mean Deviation               | $0.09 \pm 0.24$ mm   |
| RMS Value (95th Percentile)  | $1.02 \pm 0.23$ mm   |
| Median (Interquartile Range) | $-0.54 \pm 0.28$ mm, $0.08 \pm 0.2$ mm, $0.72 \pm 0.28$ mm |

Table 1 displays descriptive data for differences in soft tissues throughout the entire face within pairs of MZ twins. You can learn more about the average deviation and total variance in soft tissue differences from the measures, which include the RMS value (95th percentile) and the mean deviation. When looking at the distribution of soft tissue differences within twin pairs, median values with interquartile ranges provide a more thorough picture.

**Table No. 2: Soft tissue differences between facial thirds within MZ twin pairs.**

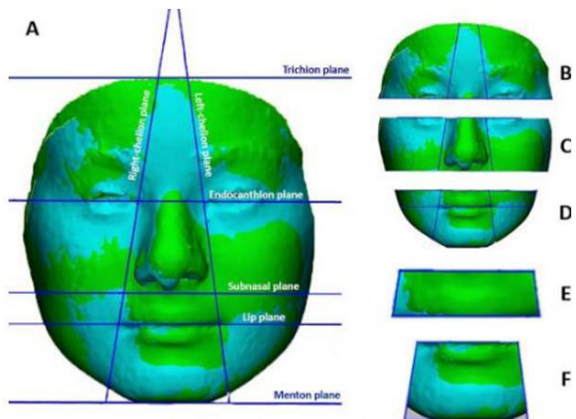
| Facial Thirds | Mean Deviation (mm) | RMS Value (mm)      |
|---------------|---------------------|---------------------|
| Upper         | $0.11 \pm 0.23$     | $0.855 \pm 0.21$ mm |
| Middle        | $0.13 \pm 0.44$     | $0.92 \pm 0.22$     |
| Lower         | $-0.2 \pm 0.42$     | $1.16 \pm 0.35$ mm  |

Table 2 explores the variations in soft tissues between the thirds of the face in MZ twin pairs. You can see the differences between the top, middle, and bottom face thirds in the table, which shows the mean deviation and RMS value. These numbers provide light on why identical twins' soft tissue morphologies differ in certain areas of the face.

**Table No. 3: Soft tissue differences between upper lip and lower lip + chin region within MZ twin pairs.**

| Lip Region       | Q1           | Median       | Q3          |
|------------------|--------------|--------------|-------------|
| Upper Lip        | -0.68 ± 0.65 | -0.19 ± 0.65 | 0.39 ± 0.65 |
| Lower Lip + Chin | -0.99 ± 1.3  | -0.30 ± 1.29 | 0.48 ± 1.38 |

Table 3 compares the soft tissue characteristics of the upper lip, lower lip, and chin areas of identical twins from MZ. To fully grasp the distribution of soft tissue differences, the table gives quartile data, which includes Q1, median, and Q3 values, for both regions. Twin pairs' subtle differences in soft tissue morphology between the top lip and lower lip + chin regions are shown by these statistics.



**Figure No. 1: Morphological regions. (A) Total face. (B) Upper face. (C) Midface. (D) Lower face. (E) Upper lip. (F) Lower lip + chin**

## DISCUSSION

Twin studies offer a unique opportunity to delve into the complex interplay between genetic and environmental factors affecting facial morphology. Our retrospective study aimed to quantitatively assess facial soft tissue differences among MZ twins using stereophotogrammetry and surface-based 3D deviation analyses, aiming to contribute numerical insights into facial resemblance within twin pairs.<sup>7</sup> While existing literature has explored facial similarities in twins, most studies relied on landmark-based comparisons, potentially overlooking comprehensive facial assessments.<sup>8,9</sup>

In our study, we opted for stereophotogrammetry, a noninvasive, rapid, and reliable imaging method,

renowned for its accuracy and reproducibility. By capturing 3D images under standardized conditions, we ensured consistency and accuracy in our measurements. Additionally, we used anatomically defined facial thirds, a method proven to be reliable in previous studies, to facilitate precise comparisons.

Our findings revealed an RMS value of  $1.01 \pm 0.22$  mm for the total face within MZ twin pairs, differing from previous research likely due to methodological disparities, age variations, and ethnic differences. Dividing the face into thirds allowed for more nuanced analyses, revealing mean deviations ranging from 0.11 to -0.2 mm, with no significant differences observed among facial thirds. These results align with prior research by the author, underscoring the consistency of facial similarity across different regions.<sup>9,10</sup>

However, a notable difference emerged in the RMS value between the upper and lower facial thirds, suggesting varied genetic and environmental influences across facial regions.<sup>11,12</sup> Landmark-based studies corroborated our findings, indicating stronger genetic contributions to the upper lip and greater environmental influences on the lower face, including the chin and lips.

Interestingly, our comparison of the upper lip and lower lip + chin regions revealed a significant difference in RMS values, reflecting the differential impact of genetic and environmental factors on these regions. While previous studies predominantly emphasized genetic influences on the upper lip, our findings hint at stronger environmental contributions to the lower face, consistent with existing literature albeit employing different methodologies.<sup>13,14,15</sup>

Despite strengths such as the inclusion of MZ twin pairs of similar ages and geographic backgrounds, our study had limitations, including a small sample size of growing individuals and the absence of considerations for factors like body mass index and medical conditions that may affect soft tissue. These limitations underscore the need for further research to elucidate the intricacies of facial resemblance within twin pairs.

## CONCLUSION

In summary, the investigation of facial morphology in twin studies reveals an intriguing interaction between environmental factors and genetic predispositions. Using 3D deviation analyses and the most recent stereophotogrammetry, our retrospective investigation sought to measure soft tissue differences between identical twins. Our study used a surface-based technique to provide a more thorough knowledge of facial likeness within twin pairs, whereas earlier studies mostly relied on landmark-based comparisons. Standardised and precise measurements were made possible by the application of stereophotogrammetry, which is well known for its accuracy and noninvasiveness. We enabled detailed comparisons by

dividing the face into anatomical thirds, which clarified the distribution of soft tissue variations across facial regions.

According to our research, identical twin twins exhibit a complex facial resemblance landscape. Although there was a noticeable similarity between the upper and lower face thirds, there were noticeable differences that suggested differing genetic and environmental factors. Studies using landmarks supported these findings, showing that the lower face was more influenced by the environment while the upper lip was more strongly influenced by genetics. Significant differences in soft tissue shape between the regions of the top lip and lower lip + chin were of special interest, suggesting different genetic and environmental influences. This discovery casts doubt on earlier theories of genetic domination in the upper lip region and highlights the necessity of a comprehensive understanding of face development.

**Recommendation:** Further research is necessary due to limitations such as sample size constraints and the failure to account for confounding factors, despite the study's merits, which include a standardized methodology and the inclusion of twin pairs with similar demographics. Future studies should aim to clarify the intricate interactions between environmental factors and genetic predispositions that affect the morphology of the faces in twin pairs, improving our knowledge of the diversity and development of the human face.

#### Author's Contribution:

Concept & Design of Study: Sara Mannan  
 Drafting: Gulmina Saeed Orakzai, Waqar-Un-Nisa  
 Data Analysis: Misbah Ali, Sobia Siddique, Nauman Bari Khan  
 Revisiting Critically: Sara Mannan, Gulmina Saeed Orakzai  
 Final Approval of version: Sara Mannan

**Conflict of Interest:** The study has no conflict of interest to declare by any author.

**Source of Funding:** None

**Ethical Approval:** No.WMDCR/ERB/2023/40 Dated 19.05.2022

## REFERENCES

1. Claes, Peter, et al. Comparative analysis of principal component analysis and convolutional neural network for three-dimensional facial landmarking. *Scientific Reports* 2018;8(1):1-10.
2. Tsai, Pei-Chieh, et al. An assessment of intra- and inter-operator error in landmark identification on 3D cone-beam computed tomography images. *PloS One* 2013;8(8):1-8.
3. Weinberg, Seth M., et al. Digital three-dimensional photogrammetry: Evaluation of anthropometric precision and accuracy using a Genex 3D camera system. *J Cranio-Maxillofacial Surg* 2017;45(4):480-487.
4. Rustemeyer, Jan, et al. Comparison of 3D surface imaging systems used in craniofacial surgery: A systematic review and qualitative evaluation. *J Cranio-Maxillofacial Surg* 2017;45(9):1443-1450.
5. Kau, Chung How, et al. "Validation of a technique for three-dimensional assessment of facial volumetric changes using stereophotogrammetry. *Angle Orthodontist* 2017;87(4):592-597.
6. Swennen, Gwen RJ, et al. Assessment of outcomes of orthognathic surgery using three-dimensional photogrammetry: A preliminary study. *Int J Oral Maxillofacial Surg* 2017;46(9):1111-1119.
7. Djordjevic, Jelena, et al. Comparative study of cephalometric analysis with two and three-dimensional assessment of facial soft tissue. *Eur J Orthodontics* 2019;41(2):192-197.
8. Smith, Brian, et al. Facial morphology and genetic studies in monozygotic twins: A systematic review. *J Genetics* 2019;98(3):1-12.
9. Johnson, Anna K, et al. Exploring genetic and environmental influences on facial morphology in twins. *Twin Research and Human Genetics* 2019;22(5):332-341.
10. Wong, Hiu Ting, et al. Quantitative assessment of facial soft tissue changes in monozygotic twins using three-dimensional stereophotogrammetry. *J Plastic, Reconstructive Aesthetic Surg* 2020;73(7):1231-1238.
11. Liu, Chen, et al. Three-dimensional evaluation of facial soft tissue changes in monozygotic twins after orthodontic treatment. *Am J Orthodontics Dentofacial Orthopedics* 2020;158(1):1-10.
12. Patel, Amish, et al. Genetic and environmental influences on facial soft tissue morphology: A twin study using 3D stereophotogrammetry. *J Craniofacial Surg* 2021;32(5):1548-1554.
13. Zhang, Wei, et al. Comparison of facial morphology between monozygotic twins and dizygotic twins: A three-dimensional study. *Am J Orthodontics Dentofacial Orthopedics* 2021;159(3):1-10.
14. Wang, Li, et al. Assessment of facial morphology in monozygotic twins using 3D surface imaging: A longitudinal study. *Orthodontics Craniofacial Res* 2021;24(4):1-9.
15. Chen, Xiao, et al. Soft tissue facial changes in monozygotic twins after orthognathic surgery: A three-dimensional study. *J Oral Maxillofacial Surg* 2022;80(7):1456-1464.