

Outcomes of Endoscopic Treatment of Ureterocele in Children and Adults: Our Experience

Hameed-ur-Rehman Bozdar¹, Nisar Ahmed Shaikh², Muhammad Iqbal Soomro² and Malik Hussain Jalbani²

ABSTRACT

Objective: To assess the safety, complication and results of endoscopic treatment of ureterocele.

Study Design: Retrospective cohort study.

Place and Duration of Study: This study was conducted at the Urology Department CMCH Larkana and Khairpur Medical College Hospital, Khairpur from June 2011 to January 2014.

Materials and Methods: 22 cases of ureterocele at Urology Department CMCH Larkana and Khairpur Medical College Hospital Khairpur was conducted. Standard method of endoscopic surgery like endoscopic deroofting in adults and endoscopic incision in children carried out.

Results: Out of 22 patients, 12 (54.5%) were female and 10 (45.5%) male. The age of the patients ranged from 5 to 30 years. Mean age of patients was 16.3 with SD±8.7. The presenting features were lumbar pain in 17 (77.3%) cases, urinary tract infection in 3 (13.6%), and in 2 (9.1%) cases it was detected incidentally. All patients successfully treated by endoscopic surgery. Minor complication occurs like haematuria and UTI in 5 (22.7%), which treated medically.

Conclusion: Endoscopic treatment for ureterocele is safe and cost effective surgery and least post operative complication.

Key Words: Ureterocele, endoscopic treatment, children.

Citation of articles: Bozdar HR, Shaikh NA, Soomro MI, Jalbani MH. Outcomes of Endoscopic Treatment of Ureterocele in Children and Adults: Our experience. Med Forum 2017;28(7):48-50.

INTRODUCTION

Ureterocele is a cystic out-pouching of the found in the distal ureter balloons due to a delay in Chawall's membrane absorption.¹ Ureteroceles occur in 1 in every 4000 children and occur most common in whites. Females are affected 4-7 times more often than males and common on left-side. Approximately 10% of ureterocele are bilateral. Ureteroceles may be categorized based on their relationship with the renal unit or based on distal ureteral configuration and location. Single-system ureteroceles are those associated with a single kidney, collecting system, and ureter, Duplex-system ureteroceles are associated with kidneys that have completely duplicated ureters, Orthotopic (intravesical) ureterocele is a term used for a ureterocele contained within the bladder. An orthotopic ureterocele may prolapse into and beyond the bladder neck, but the origin of the walls of an orthotopic ureterocele are contained within the bladder.

The orthotopic ureterocele usually arises from a single renal unit with one collecting system and is more commonly diagnosed in adults. Ectopic (extravesical) ureterocele refers to ureteroceles with tissue that originates at the bladder neck or beyond, into the urethra. They typically arise from the upper pole moiety of a duplicated collecting system and are more common in the pediatric population. Another method of classifying ureterocele is based on location and configuration. Stephens proposed a classification system based on the features of the affected ureteral orifice, as follows: Stenotic ureteroceles are located inside the bladder with an obstructing orifice, Sphincteric ureteroceles lie distal to the internal sphincter. The ureterocele orifice may be normal or patulous, but the distal ureter leading to it becomes obstructed by the activity of the internal sphincter, Sphincterostenotic ureteroceles have characteristics of both stenotic and sphincteric ureteroceles and Cecoureteroceles are elongated beyond the ureterocele orifice by tunneling under the trigone and the urethra. At present, this classification is used infrequently. The characterization based on the location of the orifice (intravesical vs ectopic) is more commonly used because it has therapeutic implications.² Ureteral atony and stasis of urine in the ureterocele can precipitate calculus formation. The prevalence of calculus in a single ureterocele is variable (ranging between 4% and 39%).^{1,3} Orthotopic ureterocele occur in 17-35% of

¹. Department of Urology, Khairpur Medical College Hospital, Khairpur.

². Department of Urology, CMCH Larkana

Correspondence: Dr. Hameed-ur-Rehman, Assistant Professor, Department of Urology, Khairpur Medical College Hospital, Khairpur.

Contact No: 0300-4296188

Email: drhameedbalouch@gmail.com

Received: May 11, 2017;

Accepted: June 09, 2017

cases, with an incidence of ectopic ureterocele of about 80% in most pediatric series. Similarly, about 80% of ureterocele are associated with the upper pole moiety of a duplex system. When ectopic ureterocele are associated with duplicated collecting systems, the upper pole moiety usually dysplastic or poorly functioning. Single-system ectopic ureterocele are uncommon and are most often found in males^{4,5}. The pediatric and adult conditions are often found only through diagnostic investigation like ultrasound and X-Ray IVU.^{1,5} Ureterocele classified as Intravesical, Ectopic, Stenotic (Intravesical ureterocele with a stenotic opening), Sphincteric (Ectopic ureterocele with an orifice distal to the bladder neck), Sphincterostenotic (Orifice is stenotic and distal to the bladder neck) and Cecoureterocele (Ectopic ureterocele that extends into the urethra, but the orifice is in the bladder).⁴ Usually presenting with lumbar pain, Frequent urinary tract infection, Urosepsis, Obstructive voiding symptoms, Urinary retention, Failure to thrive, Hematuria, Ureteral calculus and cobra head sign is seen in radiography.^{6,7} Symptomatic ureterocele require proper treatment like excision and ureteric reimplantation while now a day endoscopic treatment is the choice treatment for ureterocele. our aim of study to see the efficacy and safety of endoscopic incision and deroofing of ureterocele in children and adult patients.

MATERIALS AND METHODS

A retrospective cohort study of 22 cases of ureterocele carried from June 2011 to January 2014 at urology department CMCH larkana and Khairpur medical college hospital Khairpur. All patients diagnosed on ultrasound and X-Ray IVU. Fig.No.1 Patients having upper tract pathology and diabetic excluded from the study. Standard method of endoscopic surgery like endoscopic deroofing in adults and endoscopic incision in children carried out while 12(54.5%) patients having stone in ureterocele so litholapaxy done after endoscopic surgery.

RESULTS

Out of 22 patients, 12 (54.5%) were female and 10 (45.5%) male (Fig.No.2). The age of the patients ranged from 5 to 30 years. Mean age of patients were 16.3 with $SD \pm 8.7$. The presenting features were lumbar pain in 17 (77.3%) cases, urinary tract infection in 3 (13.6%), and in 2 (9.1%) cases it was detected incidentally (Fig.No.3). All patients successfully treated by endoscopic surgery. 12 (54.5%) patients having stone in ureterocele so litholapaxy done after endoscopic surgery (Fig.No.4). Minor complication occurs like haematuria and UTI in 5 (22.7%).

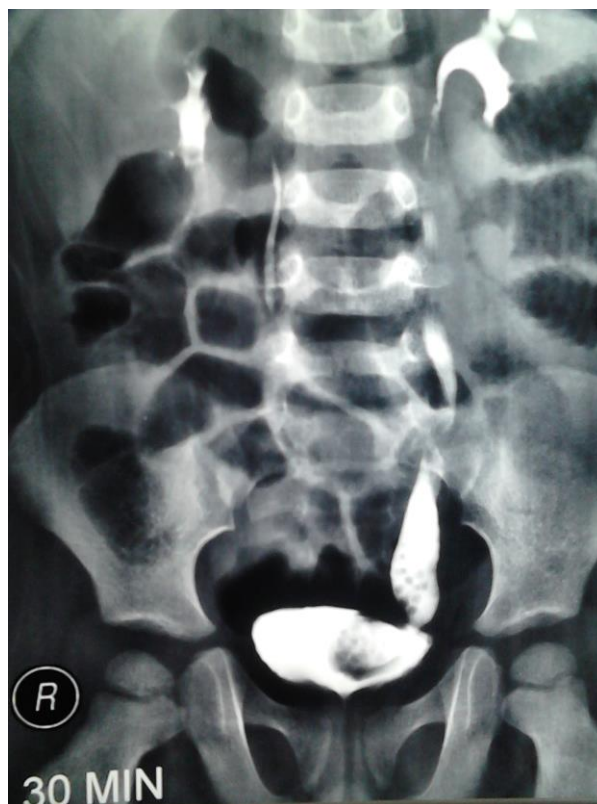

Figure No. 1: X-Ray Ivp Showing Ureterocele With Stone

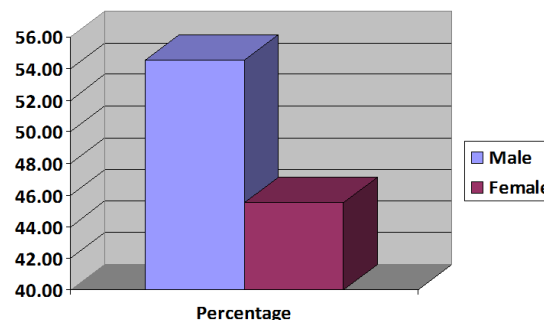


Figure No. 2: Male to female percentage of ureterocele

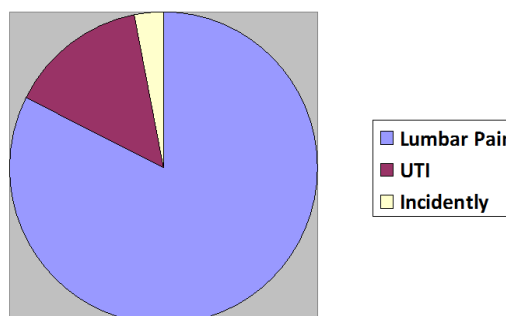


Figure No.3: Percentage of ureterocele presentation

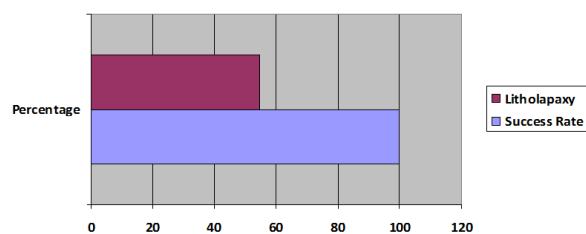


Figure No.4: Success rate of ureterocele and litholapaxy requirement

DISCUSSION

A ureterocele is one of the more challenging urologic abnormality facing urologist. However, with proper diagnosis and treatment, the outcome remains extremely good.⁶ Indications for ureterectomy include the Recurrent UTI, Ureteral calculi and intractable pain.^{2,7} In our study 22 patients, 12 (54.5%) were female and 10 (45.5%) male. The age of the patients ranged from 5 to 30 years. Mean age 16.3 ± 8.7 which is higher in secondary data due to patients presenting in late stage due to poverty and ignorance of health problems.^{5,7} Majority of our patients presenting with lumbar pain in 17 (77.3%) cases, urinary tract infection in 3 (13.6%), and in 2 (9.1%) cases it was detected incidentally which is comparable to other studies.⁸ All patients diagnosed on ultrasound and X-Ray IVU which is also comparable to various studies. In series study approximately 10% of ureteroceles are bilateral and Orthotopic ureteroceles occur in 17-35% of cases, with an incidence of ectopic ureteroceles of approximately 80% as well as 80% of ureteroceles are associated with the upper pole moiety of a duplex system and ectopic ureteroceles are associated with duplicated collecting systems, the upper pole moiety may be dysplastic or poorly functioning but in our study three cases seen bilateral only and none congenital anomalies seen our study.^{4,10} Standard method of endoscopic surgery like endoscopic deroofing in adults and endoscopic incision in children done successfully. 12 (54.5%) patients having stone in ureterocele so litholapaxy done after endoscopic surgery which is also comparable to secondary data.^{1,9} Minor complication like haematuria and UTI occur in 5 (22.7%) cases which treated medically which is also comparable Campbell M and Singh I study.^{8,9}

CONCLUSION

Endoscopic treatment for ureterocele is safe and cost effective surgery and least post operative complication.

Author's Contribution:

Concept & Design of Study:	Hameed ur Rehman Buzdar
Drafting:	Nisar Ahmed Shaikh
Data Analysis:	Muhammad Iqbal Soomro
Revisiting Critically:	Malik Hussain Jalbani
Final Approval of version:	Hameed ur Rehman Buzdar

Conflict of Interest: The study has no conflict of interest to declare by any author.

REFERENCES

- Messing EM, Henry SC. Stones in orthotopic, non-obstructing ureteroceles. *J Urol* 1979;203:403-4.
- Schultz K, Todab LY. Genetic Basis of Ureterocele. *Curr Genomics* 2016;17(1):62-9.
- Sen V, Aydogdu O, Yonguc T, Bozkurt IH, Polat Sand Basmaci. Endourological treatment of bilateral ureteral stones in bilateral ureteral duplication with right ureterocele. *Can Urol Assoc J* 2015;9(7-8):511-3.
- Mandal S, Goel A, Kumar M et al Spontaneous erosion of ureterocele wall by stone: rare images. *Urology. J Urol* 2015: 22-23.
- Sander JC, Bilgutay BC, Stanase I, Koh CJ, Janzen ET, Gonzales DR. Roth and Seth A. Outcomes of Endoscopic Incision for the Treatment of Ureterocele in Children at a Single Institution. *J Urol* 2015;193:662-667.
- Kandpal DK, Sibal A, Srivastava R. Management of complicated ureteroceles: Different modalities of treatment and long-term outcome. *J Indian Assoc Pediatr Surg* 2014;19(3):156-58
- Stephens FD, Smith ED, Hutson JM. Congenital anomalies of the kidney, urinary and genital tracts. Oxford: Isis Medical Media, 1996.
- Singh I. Adult bilateral non-obstructing orthotopic ureteroceles with multiple calculi: endoscopic management with review of literature. *Int Urol Nephrol* 2007;2013:71-4
- Campbell M. Ureterocele: a study of 94 instances in 80 infants and children. *Surg Gynecol Obstet* 1951;2013:705.
- Schluskel RN, Retik AB. Ectopic ureter, ureterocele, and other anomalies of the ureter. In: Wein AJ, Kavousi LR, Novick AC, et al., editors. *Campbell-Walsh Urology*. 9th edn Philadelphia: WB Saunders' 2007.p.3398.