

Association Between Chewing Tobacco and Lesions of Oral Precancer

Hafiz Muhammad Rafique Tagar¹, Saima Aqil², Dost Muhammad Kalhoro³, Muhammad Abdul Hafeez⁴ and Farhan Jaleel⁵

ABSTRACT

Objective: To evaluate the association between different addictive habits and oral premalignant conditions/lesions.

Study Design: Cross sectional Study

Place and Duration of Study: This study was conducted at the Department of Biochemistry in collaboration with Clinical Oncology department of Basic Medical Sciences Institute (BMSI), Jinnah Postgraduate Medical Centre (JPMC), Karachi in 2015.

Materials and Methods: A total of 34 patients visiting the outpatient clinic of clinical oncology department with different addictive chewing habits were included in this study. Initial assessment and diagnosis was made by history and clinical examination which was subsequently confirmed histopathologically. The socio-demographic profile of the patients, type of habit and nature of lesion all were recorded. The collected data was then evaluated for its statistical significance on SPSS version 19.

Results: Out of 34 patients, 55.8% (n=19) were female while 44.2% (n=15) were males. The mean age was 39.1 years and 47% of the patients were in the 21-40 year age group. Gutka chewing was the most prevalent lifestyle habit (41.2%) followed by chaliya (29.4%), naswar (14.7%), and pan (11.7%). Leukoplakia was the most frequent precancerous lesion to be observed (58.8%) followed by oral erythroplakia (29.4%).

Conclusion: The habit of Gutka chewing showed a statistically significant association to the development of oral precancerous lesions and conditions.

Key Words: Oral precancerous lesions, Lifestyle habits, Gutka, Chaliya, Naswar, pan

Citation of article: Tagar HMR, Aqil S, Kalhoro DM, Hafeez MA, Jaleel F. Association Between Chewing Tobacco and Lesions of Oral Precancer. Med Forum 2017;28(3):33-36.

INTRODUCTION

The lesions of oral cavity constitute the major public problem in South Asian countries including Pakistan¹. The public of these areas have habits of chewing Gutka, pan and betel quid (Quid is defined as a substance or group of substances remaining in contact with the oral mucosa containing one or both of the two basic ingredients i.e. tobacco and areca nut). Chaliya/areca nut, smoking and naswar (snuff).^{11,12} These are the common addictive habits of public in this region.

Research has found that these habits are risk factors for producing oral lesions¹. A change in colour of the normal reddish oral mucosa to white constitutes one of the most frequently encountered oral abnormalities². A variety of malignant and premalignant lesions of oral cavity appear white, like leukoplakia, oral submucous fibrosis, oral lichen planus, erythroplakia and erythroleukoplakia¹. The initiation of these precancerous conditions may depend upon extrinsic local factors. The more frequently blamed factor is tobacco used in different ways i.e. smoking and chewing that causes local irritation⁴. Pindborg and Renstrup¹³ found that, smoking, chewing tobacco alone or included in pan are the causative factors for leukoplakia. They further reported that habit of keeping naswar (snuff) in the vestibule of mouth produces oral precancerous lesions⁵. Caniff³ reported that there is general agreement in the literature that the areca nut chewing is another significant causative factor for oral lesions⁶. Tilakaratne pointed out in his study that eating spicy food and chewing chaliya/areca nut are the causative factors of oral lesions^{7,8}. In our study we have examined the patients having oral mucosal lesions with deleterious chewing habits of Gutka, chaliya/ areca nut, pan, smoking tobacco, taking spicy food and using naswar and evaluated the association of these risk factors in causing oral precancerous lesions.

¹. Department of Biochemistry, Bibi Aseefa Dental College, SMBB Medical University, Larkana.

². Department of Biochemistry, Altamash Institute of Dental Medicine, Karachi.

³. Department of Biochemistry, Chandka Medical College, SMBB Medical University Larkana.

⁴. Department of Physiology, University of Sindh Jamshoro.

⁵. Department of Biochemistry, Liaquat College of Medicine and Dentistry, Karachi.

Correspondence: Dr. Hafiz Muhammad Rafique Tagar, Assistant Professor & Head, Department of Biochemistry, Bibi Aseefa Dental College, SMBB Medical University, Larkana.

Contact No: 0306-3472861

Email: drmrtagar@gmail.com

Received: January 10, 2017; Accepted: February 17, 2017

MATERIALS AND METHODS

The study was carried out on 34 patients of precancerous lesions (i.e. leukoplakia, erythroplakia and oral sub mucous fibrosis) of oral mucosa, at the department of Biochemistry, Basic Medical Sciences Institute (BMSI), in collaboration with Clinical Oncology ward of JPMC, Karachi in the last one year. The criteria of oral examination were included on the colour of oral mucosa and site of occurrence. The patients were asked about the habits of taking gutka, chaliya/areca nut, pan, spicy food, smoking, naswar and all the findings were noted in a specially designed proforma. The diagnosis of lesions was made clinically which was later confirmed by histopathological examination. Patients were categorized according to the type of lesion and using deleterious chewing habits of gutka, chaliya/areca nut, pan, spicy food, smoking, and naswar. The data was analyzed by using the SPSS (Statistical Package for Social Sciences) version 19. The results were tested for risk factors and statistical significance was evaluated by applying students-t-test and chi-square test.

RESULTS

The study involved 34 patients with suspected precancerous lesions out of which 15 (44.1%) were male and 19 (55.9%) were female. The youngest patient seen in this study was 14 years old and the oldest one was 70 years old. The mean age of study subjects being 43.97 years. The mean age for male patients was 47.28 years and female mean age was 40.66 years (Table. I, Figure. I). The lesions were provisionally labeled by clinical examination and histologically confirmed. Out of 34 Patients, 20 were diagnosed histologically as Leukoplakia, 10 patients of erythroplakia and 04

patients were of oral submucous fibrosis (Table 2, Figure 2).

Table No. I: Distribution of study subjects According to age and gender (n=34)

Age Group (years)	Male	Female	Total
Under 25	2	1	3
25-34	3	5	8
35-44	2	5	7
45-54	3	4	7
55 & above	5	4	9
Total	15	19	34
Mean ages	47.28	40.66	43.97

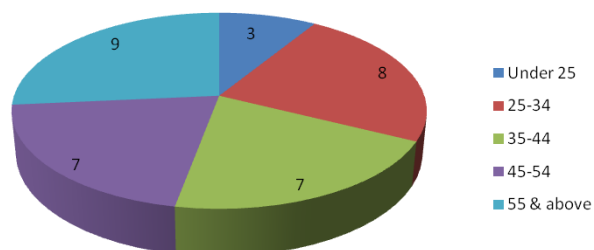


Figure No. I: Showing age wise distribution of precancerous conditions

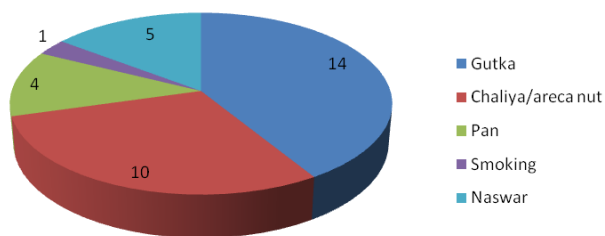


Figure No.2: Showing predisposing factors of precancerous lesions

Table No.2: Distribution of Precancerous Lesions In Relation To Predisposing Factors

Precancerous Lesions	Gutka	Chaliya/areca nut	Pan	Smoking	Naswar	Total
Leukoplakia	08	06	02	01	03	20
Erythroplakia	04	03	02	-	02	10
Oral Submucous Fibrosis	02	01	-	-	-	4
Total	14	10	04	01	05	34

All of these 34 patients were asked about their deleterious chewing habits like gutka, chaliya/ areca nut, pan, spicy food, smoking and naswar. It was observed that most of the subjects were having deleterious chewing habits of Gutka (41.2%) followed by chaliya/areca nut (29.4%), naswar (14.7%), and pan (11.7%). Some of the patients had mixed habits of using more than one of the risk substances. These predisposing factors were statistically analyzed and results showed that gutka chewing was more predominant and statistically significant risk factor with

P value <0.05 where as the association of other factors to oral premalignant lesions or conditions was not as such significant (Table. 2).

DISCUSSION

A variety of oral precancerous lesions have been identified to exist in conjunction with oral habits of chewing the deleterious addictive substances^{9,10}. In our study all the patients were habitual of chewing gutka, chaliya/areca nut, pan, spicy food, smoking or naswar in different forms and frequencies either in a single or

joined form^{1,4,11}. The gutka and chaliya/areca nut chewing habits were statistically found significant. Interpretation of data from a single institution has clear limitations. The data reflects the specific patient population reporting to this hospital and not the community as a whole. In various studies regarding the addictive habits of smoking, gutka, pan, chaliya/areca nut, spicy food, naswar etc were found in positively association with oral precancerous conditions^{8,11}. In the study of Gupta⁵, leukoplakia was seen more frequently in smokers than non smokers and reducing tobacco consumption regressed the lesion while in the study of Silverman and Griffith¹⁴ disappearance of oral leukoplakia had occasionally been reported in patients who continued to smoke. In same study the pan-chewers lesion consisted of a thick brownish black encrustation on the buccal mucosa at the site of placement of areca nut/betel quid, their study shows that the pan-chewers lesion deserve the designation of leukoplakia^{11,15,16}.

The chewing of betel quid (gutka) is practiced in several different ways in various countries, while the major components are comparatively consistent^{17,18}. In Pakistan and Southeast Asia, tobacco is usually used as an ingredient for areca nut products especially in gutka, chaliya, pan therefore it is difficult to know the individual risk effect of tobacco or areca/betel quid^{19,9,10}. A higher relative risk of oral cancer for areca/betel quid chewing with tobacco was notably higher^{20,21} than that for betel quid chewing without tobacco, and the evidence for leukoplakia as well as oral submucous fibrosis was also in the same direction^{5,7,8}.

In our study it was found that gutka, chaliya/areca nut and pan consumers were on a significant risk for the development of oral cancer which is in consistent with Khan¹¹ and Akram¹ (Table No. 2). In the study of Yang²² many oral lesions still did not have significant statistical power to clarify the effect of areca/betel quid from tobacco. In the study of Shah and Sharma²⁰ 2.6% were quid chewers, 20.8% of quid chewers had tobacco as an ingredient, 13.1% used pan masala with tobacco. For oral lesions in this study the ratio of gutka and chaliya/areca nut users was high which was comparable to our study.

In our study the gutka and chaliya/areca nut chewers were found more significant as compared with study the of Y-H Yang²² who showed in their study that chaliya/areca nut quid chewing was a significant risk factor for developing oral precancerous lesions²³.

But Mahar¹⁷ found in his study that the quid chewers with tobacco and quid chewers without tobacco were affected by oral precancerous lesions which are inconsistent with the present study. Pan was found significant in the study of Sarawathi²¹. Other so many workers have found that the chewing/smoking of Tobacco and areca nuts/betel quid usage were

positively associated for producing oral mucosal lesions^{24,25}. In the study of Hashibel⁶ the above factors were found significant in producing oral leukoplakia.

This study demonstrated a significant positive association between oral precancerous lesions and addictive chewing habits especially of gutka, chaliya/areca nut and pan^{25,9,10}. As pan is a mixture of different substances i.e. betel leaf, areca nut, tobacco, slacked lime and different other seasonings therefore the individual roles of each of these ingredients in causing oral precancerous lesions need further investigation.

CONCLUSION

The habit of gutka, chaliya/areca nut and pan chewing has showed a statistically significant association to the development of oral precancerous lesions. Therefore, it is recommended that the peoples aged ≥ 40 years who are habitual cigarette smokers, areca nut, gutka, chaliya and betel quid chewers should undergo oral mucosa screening regularly so that potential of oral precancer can be identified as early as possible. Synergistic effects endured patients with all the above habits had an over 40-fold higher risk of developing oral cavity cancer than patients who abstained.

The public should be aware of such high risk factors causing the oral precancerous lesions induced by different life styles/social addictive habits.

Conflict of Interest: The study has no conflict of interest to declare by any author.

REFERENCES

1. Akram S, Mirza T, Mirza M A, Qureshi M. Emerging patterns in clinico-pathological spectrum of Oral Cancers. Pak J Med Sci 2013;29(3).
2. Bramley PA, Simith CJ. Oral Cancer and Pre cancer establishing a diagnosis. Br Dent J 1990; 168-103.
3. Canniff JP, Harvey W, Harris M. Oral Sub mucosa fibrosis and management. Br Dent J 1986;160: 429-434.
4. Collins FM. Tobacco cessation and the impact of tobacco use on oral health. RDH. Oklahoma: Penn well dental group; 2010: 1-12.
5. Gupta PC, Mehta FS Daftary DK, Pindborg JJ, Bhonsle RB, Jalanawalk PN, et al. "Incidence rates of oral cancer and natural history in a 10 years follow up study of Indian Villages. common Dent Oral Epidemiol 1980;8:287-333.
6. Hashibe M, Sankaranarayanan R, Thomas G, Kurnvilla B, Mathew B, et al. Alcohol drinking, body mass index and the risk of oral leukoplakia in a Indian population Int J Cancer 2002;88(I): 129-134.

7. Joshi M, Patil R. Estimation and Comparative study of Serum Total Sialic Acid Levels as Tumor Markers in oral cancer and precancer. *J Can Reas and Therap* 2010;(63):263-266.
8. Jyoti S, Afzal M, Siddiue YS. Genotoxic Effects of Pann Masala and Gutica. *WORLD. J Zool* 2011; 6(3):301-306.
9. Kumar M, Riaz A, Dwivedi P, SH Thippeswamy, Khare A, Verma R. Seduced by tobacco, killed by cancer. *Inter Arch Integ Med* 2015; 2:217-222.
10. Roy SK, Chakraborty SN, Rahaman MA, Ghose G. Pattern of Smoking and Chewing Tobacco Use in a Slum of Durgapur: An Industrial City. *J Med Dent Sci* 2015;14:88-92.
11. Khan MA, Saleem S, Shahid SM, Hameed A, Qureshi NR, Abbasi Z, et al. Prevalence of oral squamous cell carcinoma (OSCC) in relation to different chewing habits in Karachi, Pakistan. *Pak J Biochem Mol Biol* 2012; 45(2):59-63.
12. Narang D, Shishodiya S, Sur, Khan NF. White blood cells count: As a pathological diagnostic marker for oral pre-cancerous lesions and conditions: A randomized blind trial. *J Carcino Mutag* 2014; 5:1-3.
13. Pindborg JJ, Murti PR, Bhonsle RB, Gupta PC, Daftari DK, Mahta FS. Oral submucous fibrosis as pre cancerous condition. *Scand J Dent Res* 1984; 92:224-229.
14. Silverman S, Ciriffith M. Smoking characteristics of patients with oral carcinoma. *J AM Dent Assoc* 1972;85:637.
15. Khadim MI. White lesions of oral musoca. *Pak Oral and Dent J* 1987;7:25-33.
16. Murti PR, Bhonsle RB, Pind Borg JJ, Daftari DK, Gupta PC, Mehta FS. Malignant transformation in oral submucous fibrosis over a 17 years period common. *Dent Oral Epidermal* 1984;13:340-341.
17. Mahar R, Lee AJ, Warnakulasuriyaka Lewis JA, Johnoson NW. Role of areca nut in the causation of oral sub mucosa fibrosis. A case control study in Pakistan. *J Oral Pathol Med* 1994;23:65 – 69.
18. Mehta FS, Gupta PC, Daftary DK, Pind borg JJ. Choksisk. An epidemiological study of oral cancer and pre cancerous conditions among 101, 761 villagers in Maharashtra India. *Int J Cancer* 1972; 24: 73-78.
19. R Rajendran, Shafers. A text book of Oral Pathology. 5th ed. Elsevier: India; 2006.
20. Shah N, Sharma PP. Role of Chewing and Smoking habits in etiology of oral submucosa fibrosis (OSF) a case control study *J Oral Pathol Med* 1998;27:475-479.
21. Saraswathi TR, Ranganathan K, Shanmugams, et al. Prevalence of Oral lesion in relation to habits: Cross-Sectional Study in South India. *Ind J Dent Res* 2006;17(3):121-125.
22. Yang YH, Lien YC, HO PS, et al. The effects of chewing areca / betelquid with and without cigarette smoking on oral submucous fibrosis and oral mucosal lesions oral disease 2005;11:88-94.
23. Tseng CH, Betel Nut Chewing Is Associated With Hypertension In Taiwanese Type 2 Diabetic Patients. *Hypertens Res* 2008;31: 417-423.
24. Sujatha D, Hebbar PB, Pai A. Prevalence and Correlation of Oral Lesions among Tobacco Smokers, Tobacco Chewers, Areca Nut and Alcohol Users. *Asian Pac J Cancer Preven* 2014; 13:1633-37.
25. Bassiony MA, Aqil M, Khalili M, Radosevich JA, Elsabaa HM. Tobacco Consumption and Oral, Pharyngeal and Lung Cancers. *Open Cancer J* 2015; 8:1-11.