

# Effect of Smokeless Tobacco Administration on Weight and Histology of Stomach in Offsprings of Swiss Albino Mice

Qadir Bux Memon<sup>1</sup>, Muhammad Bachal Pandhiani<sup>1</sup> and Zaheer Ahmed Memon<sup>2</sup>

## ABSTRACT

**Objective:** To observe and evaluate the structural changes in the stomach of the offsprings of Swiss albino mice exposed to smokeless tobacco during pregnancy.

**Study Design:** Observational / descriptive study.

**Place and Duration of Study:** This study was conducted at the Animal House of Al-Tibri Medical College Karachi from July 2015 to December 2015.

**Materials and Methods:** Female albino mice were mated. After confirmation of pregnancy 20 pregnant mice were divided into two groups of 10 each. Group A experimental was given 5% tobacco of local brand mixed with their normal chow diet along with clean water ad libitum and group B control was given normal diet along with clean water ad libitum. After 2 weeks of birth, 20 offsprings (10 male and 10 female) were selected randomly from both groups. The offsprings were sacrificed by cervical dislocation and their stomachs were removed for gross and histological analysis.

**Results:** The mean weight of stomach in experimental male offspring was found to be  $0.12 \pm 0.01$  grams, while in control group it was  $0.18 \pm 0.02$  grams. Whereas the mean weight of stomach in experimental female was found to be  $0.10 \pm 0.02$ . However in control female group it was observed as  $0.15 \pm 0.02$  grams. The difference in the mean weight of stomach between the experimental and control groups was observed to be highly significance ( $p$  Value  $< 0.001$ ) in both male and female offspring. The infection induce marked changes in the stomach, like destruction of gastric folds and glands, desquamation of endothelial cells of glands. Mild to moderate inflammatory and chronic necrotic changes with gastric atrophy were observed in microscopic findings of the gastric mucosa in smokeless tobacco treated animals. Mild dysplasia and adenomatous changes were seen in few cases of experimental animals. This lesion may result from the oral administration of toxic irritants.

**Conclusion:** The use of smokeless tobacco during pregnancy has some adverse outcomes on the offspring of mice manifested by the decrease in stomach weight as well as alter the histological features of stomach mucosa especially produces the fatty infiltration, necrotic and adenomatous changes of the gastric glands.

**Key Words:** smokeless tobacco, stomach, offspring

**Citation of article:** Memon QB, Pandhiani MB, Memon ZA. Effect of Smokeless Tobacco Administration on Weight and Histology of Stomach in Offsprings of Swiss Albino Mice. Med Forum 2016;27(12):65-69.

## INTRODUCTION

Tobacco is a plant that natively grows in America since centuries. It's harvesting steadily increasing demand of tobacco plants and that has been transported for cultivation to countries all over the world.<sup>1</sup>

"Tobacco" is a name used for plants of the genus *Nicotiana* of the Solanaceae (nightshade) family. The name is also used for the product manufactured from tobacco leaves and used in cigars, cigarettes, snuff, pipe and chewing tobacco.

Different species of the tobacco plant, with different characteristics associated with smoking have become popular in different parts of the world. The primary active ingredient of tobacco is the alkaloid nicotine, which is responsible for its narcotic and soothing qualities.<sup>2,3,3</sup> About 2,500 chemical ingredients have been detected in which many active principals are carcinogens,<sup>4</sup> like tobacco specific nitrous amide, nicotine, cadmium, arsenic, lead, chromium and nickel,<sup>5</sup> among these there are certain compounds like nicotine which can cross placental barrier is detected in fetal umbilical cord and in amniotic fluid much more beyond the maternal concentration.<sup>6</sup>

According to the World Health Organization (WHO), tobacco is the single most preventable cause of death in the world today.<sup>2,7</sup> Overall prevalence of global tobacco use among men is declining slowly while use of tobacco among women is increasing rapidly and women from developing countries are at a higher risk.<sup>8,9</sup> Pakistan is one of the few countries in the world where smokeless tobacco is widely and routinely

<sup>1</sup>. Department of Anatomy, AL-Tibri Medical College Karachi

<sup>2</sup>. Department of Anatomy, Isra University Hyderabad

Correspondence: Dr. Zaheer Ahmed Memon,  
Assoc. Prof. of Anatomy, Isra University Hyderabad Sindh  
Contact No: 0313-2851728  
Email: dr.sajidarain@gmail,  
comzaheermemon32@yahoo.com

Received: September 17, 2016; Accepted: October 29, 2016

consumed. Numerous statistics and records reported the chewing habits incidence in various communities and areas is going to increase in either gender. Various records from different sources reported that 20% of males and 17% of females use the smokeless tobacco.<sup>10,11</sup>

Smokeless tobacco has been implicated in producing numerous adverse effects in human and animals. These include epithelial changes in the oral mucosa, intestinal wall, gastric mucosa, generalized vasoconstriction, tumors of the lung, hepatomegaly, mental retardation. It also induces changes in the fetus in case of pregnant females.<sup>12</sup>

Placenta provides a vital link between the mother and the fetus. It plays the fundamental role of transferring nutrients and oxygen from the mother to the developing fetus. It also allows wasteproducts and carbon dioxide to be removed from the fetus and returns to the mother. Simultaneously it plays a role in the synthesis of hormones desired for natural development. Explants of placenta of human may be grown and observed in vitro experimentally. In a case, it was concluded that nicotine itself was capable to inhabit trophoblast differentiation, thus, hinders invasion of cytotrophoblast in a vitro assay. These authors further showed that nicotine hindered activation and synthesis of collagenase of type IV, which is essential for the invasion of cytotrophoblast.<sup>13</sup>

Subsequent to absorption, in the bloodstream nicotine enters where, the greatest nicotine affinity is in the spleen, liver, lung and kidney and lowest in the tissue of adipose. In muscle of skeletal, cotinine and nicotine concentrations are near to the whole blood. Connection of Nicotine to tissues of brain with greater affinity and noticeably accumulates in saliva and gastric juice.<sup>14</sup> Histological changes have also been reported in the stomach. As it is an organ which has the secretory role when swallowed material entering into it is converted into chyme through its enzymatic reaction.<sup>15</sup> One of current hypothesis suggested that the stomach parenchymal diseases such as chronic gastritis, hyperplasia, and fatty changes are the results of the increased toxicity caused by nicotine intake.<sup>16</sup>

However in adult human and animal model very few studies are available on the effects of smokeless tobacco or nicotine on the stomach. Since the utilization of any form of tobacco is highly common these days and in our setup not even a single study is explored on tobacco effects on the stomach mucosa of offspring of mice. The objective of the present research study is to observe the effects of the use of local chewing tobacco on the developing stomach of the offspring of mice.

## MATERIALS AND METHODS

Healthy adult male & female mice of average mean weight were obtained from animal house of Al-Tibri Medical College Karachi. Mice were kept in

plastic cages, provided with feed containers of stainless steel and stainless nozzles plastic drinkers. Mice were not forbidden to receive standard chow diet and to receive water after and before the trail. Saw dust was utilized for beddings and was amended each day. The animals were reared in the well ventilated and hygienic environment, 12 hours day light and dark cycle, and at 26°C room temperature. The experimental protocols were performed at the Al- Tibri Medical College and Animal House ATMC Karachi approved by Ethical & Research Committee Isra University Hyderabad. The cages of female mice were labeled required showing their different parameters to be observed.

All the female mice were copulated with adult male mice restricted for seven days from mating to grow their sexual urge for sex. Only one male mouse was paired with two females (GD- 0). Pregnancy was verified by mucus vaginal plug presence between 1- 10 days of pairing. On confirmation of pregnancy, the males were removed.

Twenty Pregnant Swiss albino mice were divided in two groups:

Group. A (Experimental) 10 pregnant mice

Group. B (Control) 10 pregnant mice

Female mice from day 1 till parturition were kept in separate cage (2 per cage) and tail tagged.

Group A experimental group was given 5% tobacco mixed with normal chow ad libitum along with clean water from GD-1 to parturition.

Group B control group was kept on normal feed ad libitum and clean water.

After delivery, the total of 40 offspring were selected randomly (20 offspring 10 male and 10 female) from group A and group B respectively.

Offspring of both A and B groups were divided into sub groups as follow:

Group A-1. (Experimental) 10 male offsprings

Group A-2. (Experimental) 10 female offsprings

Group B-1 (Control) 10 male offsprings

Group B-2 (Control) 10 female offsprings

After 15 days, the male and female offspring's of both control and experimental groups were sacrificed by cervical dislocation. The stomachs were removed and set in formaldehyde 10%, after which process of dehydration was conducted in alcohol ascending grades. Then the tissues were sterilized with xylene quickly to remove the alcohol. Impregnation/Infiltration was made for two molten soft paraffin wax changes for 30 minutes at 58°C each. With two L- shaped metal pieces, casting and embedding in paraffin wax was carried out and sectioning was made using a microtome. Four micron (u) thick sections were cut on rotary microtome and immersed in hot water bath. The sections were mounted on slides using a thin film of egg albumen smeared on each slide. Dewaxing was done using hot plate at 37°C and then washing with changing xylene twice was carried out. Xylene was

eliminated with absolute alcohol and at last before staining, process of hydration was carried out. The sections were marked with heamtoxylin & eosin and mounted in Canadabalsam.

To study the stomach, offspring parenchymal tissues in control and experimental groups, heamtoxylin & eosin (H&E) stained sections were used. The slides were analyzed for histopathological variations under light microscope.

**RESULTS**

While comparing the gross and histological features in the stomach of offsprings of experimental and control groups, the following results were observed.

**Weight of Stomach:** Regarding comparison of weight of stomach of offspring, it was found that in male offspring experimental group the average (mean) weight was  $0.12 \pm 0.01$  grams and the average (mean) weight of control group male offspring mice was  $0.18 \pm 0.02$  grams. (P value < 0.001). (Figure # 1)

The weight of stomach in experimental female was  $0.10 \pm 0.02$  grams and female offspring in control group was  $0.15 \pm 0.02$ .

The difference was found highly significant among both group i.e in control and in experimental groups. (P value < 0.001). (Figure # 1).

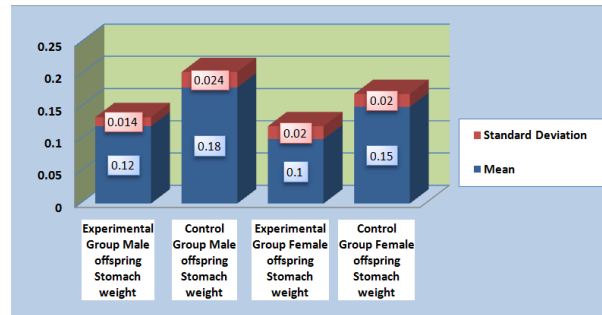


Figure No.1: Bar chart showing comparison between the mean weight of the stomach of the offsprings of both male and female in experimental and control groups. (pValue<0.001)

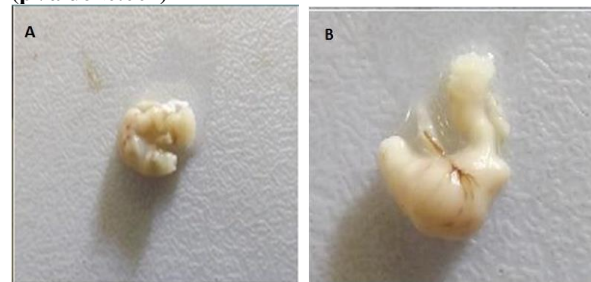


Figure No.2: (A) Stomach of experimental male offspring mouse showing gastric atrophy (B) Stomach from control male offspring mouse showing normal structure of the stomach.

**Histological Findings of Stomach of Offsprings:** The histological changes recorded in the stomach of offsprings of mice exposed to smokeless tobacco. The infection induces marked changes in the stomach, like

destruction of gastric folds and glands, desquamation of endothelial cells of glands. (Figure # 6)

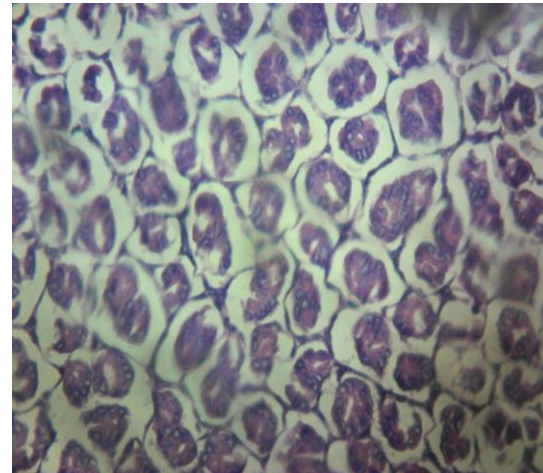


Figure No.3: Photomicrograph of H& E section of stomach from mice of control group offspring showing normal histology.

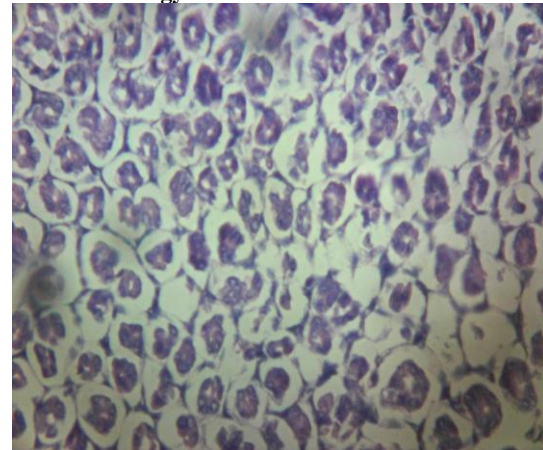


Figure No.4: Photomicrograph of H& E section of stomach from mice of experimental group offspring showing fatty infiltration.

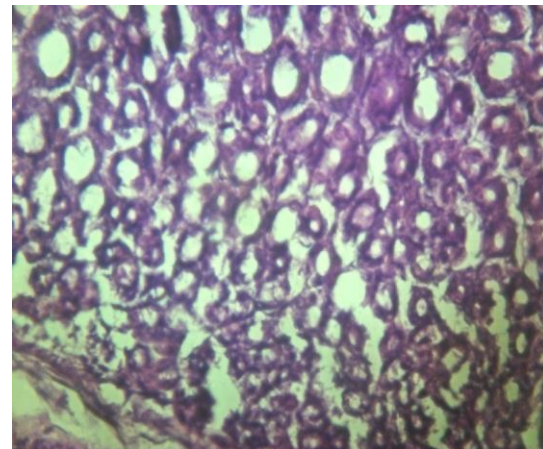
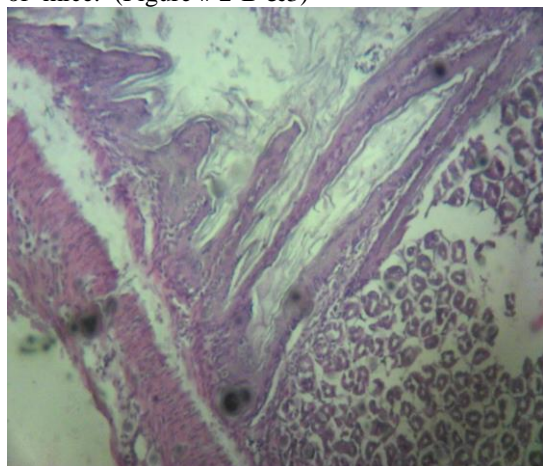


Figure-5: Photomicrograph of H& E section of stomach from male mice of experimental group offspring showing adenomatous changes.

Mild to moderate inflammatory and chronic necrotic changes (Figure # 4 & 6) with gastric atrophy (Figure # 2-A) were observed in microscopic findings of the gastric mucosa in smokeless tobacco treated animals. Mild dysplasia with adenomatous changes were seen in few cases (Figure # 5). This lesion may result from the oral administration of toxic irritants. However not significant results were observed in comparison of mucosal lesions between experimental groups of male and female offsprings.

The stomach from the control group showed normal appearance and histological structure of the offsprings of mice. (Figure # 2-B & 3)



**Figure No.6: Photomicrograph of H& E section of limiting ridge of stomach from mice of experimental group offspring showing edematous and necrotic changes of gastric glands.**

## DISCUSSION

The use of local chewing tobacco is quite common in our society especially by females whose ratio is increasing day by day. This is due to different reasons like increased social acceptance, ability to conceal it, and used in mouth fresheners. Smokeless tobacco poses a major risk to women and to the children born to them. This study was planned to observe the use of local tobacco in pregnancy outcomes especially on the stomach of offsprings in Swiss mice.

The result of our study showed the gastric atrophy and decrease in growth of stomach in tobacco treated animals. Gastric Atrophy, was diagnosed in which the extensive glandular damage, gastritis and altered metabolism of gastric glands was present. This was in agreement with the study of Chenlin Yu<sup>17</sup> & Kazuo Endoh<sup>18</sup> who have reported the similar changes in the stomach of adult experimental animals treated with nicotine.

One of the other finding in our study was a significant decrease in the relative weight of the stomach was observed in both male and female rats of the smokeless tobacco group compared with the control group. We are unable to find a comparable study probably due to the fact that the studies we have referred either do not

mention the weight of the stomach and / or have seen the effects of tobacco consumption by adult animals and have rather reported the fatty degeneration of stomach mucosa.<sup>19</sup>

The most significant finding of our study was the altered morphology and the histopathological changes in the stomach of the offsprings of the tobacco treated mothers. The main findings were the fatty infiltration of stomach parenchyma; beside it we also observed the cell swellings indicating necrotic and adenomatous changes of stomach wall of experimental animals. These findings are in agreement with the comparable findings of American Cancer Society<sup>15</sup> and Daniel N. Willis<sup>16</sup>

In the histological findings of this study, it is observed that in male offsprings the changes are more severe in comparison to female. It is due to the fact that male offsprings are more active they take more share from maternal blood and milk leading to more damage of stomach in comparison to female..

## CONCLUSION

From this study it is concluded that the use of smokeless tobacco during pregnancy has some adverse outcomes on the offsprings of mice manifested by the decrease in stomach weight as well as alter the histological features of stomach mucosa especially produces the fatty infiltration, necrotic and adenomatous changes of the gastric glands.

**Recommendation:** The society in general and females in particular are soft targets due to illiteracy, hard work and unawareness about bad effects of smokeless tobacco. Therefore they should be communicated about the information on hazards created by smokeless tobacco, especially its effect of use in pregnancy. In this way we can save them and their future generations.

**Conflict of Interest:** The study has no conflict of interest to declare by any author.

## REFERENCES

1. Ben Rapaport . Native American tobacco cultivation and use. 2007 <http://www.stogiefresh.info/edu-tobacco/articles/native-american-tobacco.html>.
2. World Health Organization, (2008). "thempower" A report on the global tobacco epidemic package. WHO Geneva.
3. Utah. Department Of Health " History of smokeless tobacco". Utah Tobacco Prevention and control Program,.2007.org/hissmkls.www. tobacco freetah pdf.
4. Borgerding MF, Bodnar JA, Curtin GM, Swauger JE. The chemical composition of smokeless tobacco: a survey of products sold in the United

- States in 2006 and 2007. *Regulatory Toxicol Pharmacol* 2012;64(3):367-87.
5. IARC Working Group on the Evaluation of Carcinogenic Risks to Humans, World Health Organization. Smokeless tobacco and some tobacco-specific N-nitrosamines. International Agency for Research on Cancer, editor. World Health Organization; 2007.
  6. Ginzler KH, Maritz GS, Marks DF, Neuberger M, Pauly JR, Polito JR, Schulte-Hermann R, Slotkin TA. Critical Review Nicotine for the Fetus, the Infant and the Adolescent?. *J Health Psychol* 2007;12(2):215-24.
  7. Siddiqi K, Shah S, Abbas SM, Vidyasagar A, Jawad M, Dogar O, Sheikh A. Global burden of disease due to smokeless tobacco, 2015. Kamran.siddiqi@york.ac.uk.
  8. Mackay J, Amos A. Women and tobacco. *Respirol* 2003;8:123-130.
  9. Centers for Disease Control and Prevention (CDC). Women and smoking: a report of the surgeon general (Executive Summary). 2002.MMWR 51: RR-12.
  10. Mahmood Z. Smoking and chewing habits of people of Karachi-1981. *J Pak Med Assoc* 1982; 32(2):34-7.7.
  11. Qidwai W, et al. Are our people health conscious? Results of a patient survey in Karachi, Pak J Ayub Medical College Abbottabad 2003;15(1):10-13.
  12. England LJ, Bunnell RE, Pechacek TF, Tong VT, McAfee TA. Nicotine and the Developing Human: A Neglected Element in the Electronic Cigarette Debate. *Am J Prev Med* 2015;49(2):286-93.
  13. Lenz B, Müller CP, Stoessel C, Sperling W, Biermann T, Hillemacher T, et al. Sex hormone activity in alcohol addiction: integrating organizational and activation effects. *Progress in neurobiol* 2012;96(1):136-63.
  14. Neal L. Benowitz, Janne Hukkanen, and Peyton Jacob, . Nicotine Chemistry, Metabolism, Kinetics and Biomarkers *Handb Exp Pharmacol* 2009; (192):29-60.
  15. American Cancer Society(2013) Smokeless Tobacco.<http://www.cancer.org/cancer/cancer-causes/tobaccocancer/smokeless-tobacco>
  16. Willis DN, Popovech MA, Gany F, Hoffman C, Blum JL, Zelikoff JT. Toxicity of gutkha, a smokeless tobacco product gone global: is there more to the toxicity than nicotine?. *Int J Environmental Res Pub Health* 2014;11(1):919-33.
  17. Yu C, Zhang Z, Liu Y, Zong Y, Chen Y, Du X, Chen J, et al. Toxicity of Smokeless Tobacco Extract after 184-Day Repeated Oral Administration in Rats. *Int J Environmental Res Pub Health* 2016;13(3):281.
  18. Endoh K, Leung FW. Effects of smoking and nicotine on the gastric mucosa: a review of clinical and experimental evidence. *Gastroenterol* 1994; 107(3):864-78.
  19. US Department of Health and Human Services. The health consequences of smoking: a report of the Surgeon General. Atlanta, GA: US Department of Health and Human Services, Centers for Disease Control and Prevention, National Center for Chronic Disease Prevention and Health Promotion, Office on Smoking and Health 2004;62..