

Prevalence of Tooth Transposition among Pakistani Population

Muhammad Ashfaq and Syed Sheeraz Hussain

ABSTRACT

Objective: The objective of this study was to determine the prevalence of tooth transposition among Pakistani population

Study Design: Observational / descriptive study

Place and Duration of Study: This study was carried out in the Department of Orthodontics Karachi Medical and College, Karachi from September 2013 to April 2014.

Materials and Methods: This study was done with panoramic radiographs of 530 subjects (210 males, 320 females). For each patient variables like age, sex, presence of tooth transposition, type, location and classification of tooth transposition.

Results: Tooth transposition was found in 09 subjects (1.69%) (8 females and 1 male). The most commonly involved transposition was found in Maxillary canine and lateral incisor (66.67 %).The frequency of complete transposition was 30% (3 out of 10) , it was found more on left side than right side(7/3).all transpositions were found in maxilla.

Conclusion: The tooth transposition was found in 1.69% in a sample of Pakistani population and transposition between upper canine and lateral incisor was the most commonly observed transposition.

Key Words: tooth transposition, Population, KMDC

Citation of article: Ashfaq M, Hussain SS. Prevalence of Tooth Transposition among Pakistani Population. Med Forum 2016;27(7):22-25.

INTRODUCTION

Transposition is a abnormality of tooth alignment in which two adjacent teeth have erupted in interchanged positions in the dental arch. In a complete transposition both the crown and root structures are transposed. In a pseudotransposition (also known as incomplete transposition) crowns of the adjacent tooth change in positional location but the root remain in the normal tooth order.¹ (figure 1).

Anomalies in number of tooth, shape of teeth and their position may alter arch length which may disturb occlusion and it may affect the treatment plan for the orthodontists. Transposed teeth has a multifactorial etiology including both genetic and environmental factors. Transposition is often associated with other dental anomalies e.g. hypodontia, peg laterals² and retained primary teeth. Frequent association between dental anomalies provides a strong argument for a genetic basis, however studies have also found evidence for local rather than genetic factors being the predominant aetiological component.³

Department of Orthodontics, Karachi Medical and College, Karachi

Correspondence: Mr. Muhammad Ashfaq,
Fcps Trainee, Department of Orthodontics, Karachi Medical
Dental College, Karachi.
Contact No.: 0321-2565127
E-mail: ashfaqyounus231@hotmail.com

Received: March 22, 2016;

Accepted: April 27, 2016

Tooth transposition is a rare condition and is related to abnormal occlusal relationship.⁴ According to Ruprecht A et al, 1985 in a study tooth transposition is prevalent in less than 1% population⁵ and it affects both males and females almost in equal ratios ,it was also seen that transposition affects the permanent dentition unilaterally as well as bilaterally , but most of the cases were unilateral,⁶ according to Joshi MR left side more involved than right⁷. The upper canine is the tooth which is most commonly displaced.⁸ When that canine is displaced in the palatolabial plane, it might be become palatally or buccally impacted. When it is displaced mesially or distally, this ectopically erupting maxillary canine may be found transposed with either of the teeth adjacent to it⁹.

Tooth transpositions can be classified according to peck and peck's¹⁰. Maxillary canine and first premolar (Mx C-P1), maxillary canine and lateral incisor (Mx C - lat), maxillary canine and first molar site (Mx.C - M1), maxillary lateral incisor and central incisor (MxI2 -I1), maxillary canine and central incisor site (Mx C - I1), and mandibular lateral incisor and canine (Mn.I2 -C).

Since there is not enough data in published form about tooth transposition in Pakistani population our study was to determine the prevalence of tooth transposition among Pakistani population.

Operational Definitions: Tooth transposition was observed on panoramic radiographs of patients. A Tooth was considered transposed when there was a interchange of positions between two adjacent teeth or

eruption of a tooth in a position which normally occupied by non-adjacent tooth¹¹. Transposition was called complete when both crown and root exchange their position in dental arch whereas was called incomplete or pseudo transposed when crown exchanged positions while roots were in their normal position.

MATERIALS AND METHODS

A observational / descriptive study was performed and the data was collected from 530 panoramic radiographs of the patients subjected to department of orthodontics, Karachi medical and dental college, (Karachi, Pakistan) between September 2013 to April 2014. The patients were included on the basis of inclusion and extrusion criteria. Convenient sampling technique was used to induce the patients in the study.

Inclusion criteria: Selection criteria of the samples included:

- The patients who were not with any syndromic features.
- The patient were not diagnosed with illness involved odontogenesis and dental eruption.

Exclusion criteria: Those patients who were previously orthodontically treated were excluded from the study.

All radiographs were taken when the patient presented for orthodontic diagnosis. Those radiographs were then examined under ample light, to determine transpositions. Radiographs were reviewed and discussed with an orthodontic consultant to assure the correction of diagnosis. The radiographs which were not of good quality were not selected for study. The data recorded for each subject with tooth transposition: included age of patient, sex, type of transposition, classification and location at which tooth transposition was present.

RESULTS

It was found that transposition was present in 09 subjects (1.69%). 8 out of those 9 were females and 1 was male with a 8:1 female to male ratio. There were ten transpositions in total that were found in 9 subjects.

Table No.1: Prevalence of tooth transposition.

Gender	n	Transposed subjects	Frequency	Total
Male	210	01	0.47 %	09 [^] (1.69%)
Female	320	08	2.50 %	

The most commonly involved transposition was found in Maxillary canine and lateral incisors in 6 subjects which is 66.67 %, secondly Maxillary canine and first premolar were found in 2 subjects (22.22 %) ,and Maxillary central and lateral incisor were found in only one subject that is 11.11%. All of transpositions were found in maxilla, and it was more common on left

side than right side with seven transpositions were found on left side compare to only three on right side. One subject have bilateral transpositions on both sides of the arch rest had only unilateral transposition. Two transpositions out of 10 were complete while remaining eight were incomplete transpositions.

Table No.2: Type, location and symmetry of tooth transposition

	MX.C-12	MX12-II	Mx.C-P1	Total
No of subjects	06 (66.67%)	01 (11.11%)	02 (22.22 %)	09 (1.69 %)
Male: Female	1 : 5	0 : 1	0 : 2	1 : 8
Complete: incomplete	2 : 5	1 : 0	0 : 2	3 : 7
Unilateral: bilateral	5 : 1	1 : 0	2 : 0	8 : 1
Left: Right	5 : 2	1 : 0	1 : 1	7 : 3

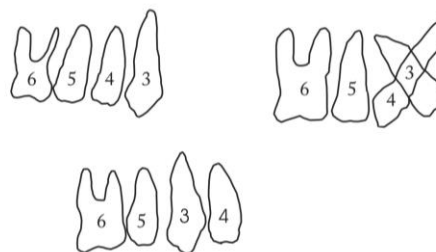


Figure No.1: Tooth transpositions

DISCUSSION

Dental anomalies like size of tooth, their number and position, as well as the developmental timing of teeth etiologically have been suggested to be of genetic and hereditary origin. It has been observed from various studies in different families and monozygotic twins, and by various observations of associations of many dental anomalies.¹² Orthodontic treatment can be affected if those dental anomalies are not considered in diagnosis and treatment planning. The results of various studies have shown variation in tooth anomalies.

The frequency of tooth transposition found in our study is 1.69 % which is different from results shown in their studies by Mevlut Celikoglu (0.27%)¹³ and Yılmaz et al¹⁴. Sample size in this study was smaller than different studies done regarding tooth transposition which could be the reason of difference in the results. Results shown in this study are close to those shown by a study in Nigeria (1.4 %)¹⁵. There seems to be a difference between gender as tooth transposition is concerned. Some studies have shown that transposition is found more frequently in females^{Error! Bookmark not defined.}. Like shapira's study showed transposition in 40 females compared to 25 males, while some reports have shown that it was found frequently in males¹⁶. Chattopadhyay found in his study that tooth transposition was found more in

males than females with a ratio of (2.5:1 male/female). In our study transposition was frequently found in females (8 subjects) with only a single male subject with transposition. Since our sample was from orthodontic department so it was justified as female seek more orthodontic treatment than males.

Several studies have shown that maxillary canines are the most frequently transposed teeth which are mostly transposed with lateral incisor or premolars^(Error! Bookmark not defined.,Error! Bookmark not defined.,Error! Bookmark not defined.). Maxillary canine first premolar transposition may have a retained deciduous canine, permanent canine itself may be blocked out buccally between first and second premolar along with mesiolabial rotation. The transposed first premolar may be rotated mesiolabially 90 deg or may be blocked out palatally. In maxillary canine and lateral incisor transposition features may include retained deciduous, blocked in labial region or a rotated canine and lateral incisor, small laterals or congenitally absent second premolars or impacted canine or a central incisor on the side of transposition. Transposition can also be found between maxillary central and lateral incisors but these cases are extremely rare.¹⁷ One case of asymmetric tooth transposition have been found in a study¹⁸. The patient in that study was a male having upper canine and premolar tooth found transposed on right side and mandibular canine and lateral incisor were found transposed on left side. In this study most of the cases were involving maxillary canines which were frequently transposed with the lateral incisors, as they were six subjects in which there was this sort of transposition (66.67%), this result was quite similar to that of shown in the results by Chattopadhyay and Srinivas^(Error! Bookmark not defined.). Results in this study showed only two cases (22.22%) with maxillary canine premolar transpositions which was different from the results shown by Plunkett et al^(Error! Bookmark not defined.). However this was similar to studies by Chattopadhyay¹⁶ and Srinivas¹⁷ who reported more frequent occurrence of Mx C-I2 transposition. Only one case shows transposition in maxillary central and lateral incisor.

Going through number of studies there seems to be more frequent cases of maxilla over mandible in tooth transposition. It can be thought that due to high density of bone present in mandible may decrease the occurrence of tooth transposition, this seems to be the reason which justifies greater incidence of maxillary occurrence¹⁹. This study also shows similar results as all the transpositions were found in maxilla. Unilateral transpositions are found more frequently in this study as compared to bilateral (8 to 1 respectively). These results are similar to study by Shapira and many others¹¹. This increased frequency of unilateral cases can be linked to the reason that bodies and faces are not perfectly symmetrical in any individual. That minor

asymmetry also affect dental arches in term of length between the two sides which, in extreme cases, can result in the form of transposition²⁰. Some studies^(Error! Bookmark not defined.,Error! Bookmark not defined.,Error! Bookmark not defined.) have shown greater frequency on left side while some studies **Error! Bookmark not defined.** showed that left and right sides are equally affected. Our study shows that left side is more affected than right side since 7 transpositions were found on left side while 3 transpositions were found on right side (7:3).

CONCLUSION

As the results found in the study showed that transposition was commonly found in maxilla with canine is the most commonly involved tooth which transposed with lateral incisor (66.67%) and with premolar (22.22%). Females (88.88%) presented with more transpositions than those that were found in males. Most of the transpositions were unilateral cases (88.88%) with more were on left side (70%). Transposition is a rare anomaly and early diagnosis of it can help orthodontists to manage the patients in appropriate way.

Conflict of Interest: The study has no conflict of interest to declare by any author.

REFERENCES

1. Nicola J, Martyn S, Martyn CT. Dental transposition as a disorder of genetic origin. *Eur J Orthod* 2006;2:145-51.
2. Simon C. Maxillary canine anomalies and tooth agenesis. *Eur J Orthod* 2005;27:450-6
3. Shapira Y, Kufnec MM. Maxillary tooth transpositions characteristic features and accompanying dental anomalies. *Am J Orthod Dentofacial Orthop* 2001; 119:127-134
4. Hatzoudi M, Papadopoulos MA. Prevalence of tooth transposition in Greek population. *Hell Orthod Rev* 2006; 9:11-22.
5. Ruprecht A, Batniji S, Neweihi E. The incidence of transposition of teeth in dental patients. *J Paedod* 1985;9:244-249
6. Plunkett DJ, Dysart PS, Kardos TB, Herbison GP. A study of transposed canines in a sample of orthodontic patients. *Br J Orthod* 1998;25:203-8.
7. Joshi MR, Bhatt NA. Canine transposition. *Oral Surg Oral Med Oral Pathol* 1971;31:49-54.
8. Shapira Y. Transposition of canines. *J Am Dent Assoc* 1980;100:710-2.
9. Shapira Y, Kufnec MM. Maxillary tooth transpositions characteristic features and accompanying dental anomalies. *AJODO* 2001; 119:127-134

10. Peck S, Peck L. Classification of maxillary tooth transpositions. *Am J Orthod Dentofacial Orthop* 1995;107:505-1.
11. Peck L, Peck S, Attia Y. Maxillary canine-first premolar transposition, associated dental anomalies and genetic basis. *Angle Orthod* 1993;63:99-109.
12. Baccetti T. A controlled study of associated dental anomalies. *Angle Orthod* 1998;68:267-74.
13. Celikoglu M, Miloglu O, Oztek O. Investigation of tooth transposition in a non-syndromic Turkish Anatolian population: Characteristic features and associated dental anomalies, *Med Oral Patol Oral Cir Bucal* 2010;15 (5):e716-20.
14. Yilmaz HH, Türkkahraman H, Sayin MO. Prevalence of tooth transpositions and associated dental anomalies in a Turkish population. *Dentomaxillofac Radiol* 2005;34:32-5
15. Onyeaso CO, Onyeaso AO. Occlusal/dental anomalies found in a random sample of Nigerian schoolchildren. *Oral Health Prev Dent* 2006;4: 181-186.
16. Chattopadhyay A, Srinivas K. Transposition of teeth and genetic etiology. *Angle Orthod* 1996; 66:147-52.
17. Peck S, Peck L. Classification of maxillary tooth transpositions. *Am J Orthod Dentofacial Orthop* 1995;107:505-17.
18. Al-Shawaf MD. Bilateral asymmetrical transposition of teeth. Report of a case. *Ann Dent* 1988;47:41-3.
19. Papadopoulos MA, Chatzoudi M, Karagiannis V. Assessment of characteristic features and dental anomalies accompanying tooth transposition: a meta-analysis. *Am J Orthod Dentofacial Orthop* 2009;136:308.e1-10.
20. Gholston IR, Williams PR. Bilateral transposition of maxillary canines and lateral incisors: a rare condition. *ASDC J Dent Child* 1984;51:58-63.