

Intramedullary Nailing for Open Fractures of the Tibial Shaft

1. Naveed Ishaq Malik 2. Pervaiz Iqbal 3. Ilyas Rafi 4. Wasif Ali Shah

1. Asstt. Prof. of Orthopaedic, CMH, Lahore 2. Assoc. Prof. of Orthopaedic, Shaikh Zayed Hospital, Lahore
3. Asstt. Prof. of Orthopaedic, Shaikh Zayed Hospital, Lahore 4. Asstt. Prof. of Orthopaedic, CMH, Lahore

ABSTRACT

Background: Interlocking intramedullary nailing has become a popular method of fixation for closed tibial fractures, and a series of reports has confirmed excellent results with this technique. However, the use of intramedullary nails for open tibial fractures is controversial. The standard treatment for these injuries has been external fixation, particularly for fractures associated with more severe soft-tissue injuries.

Objective: The purpose of the present study was to compare the clinical and radiographic results of intramedullary nailing of open fractures of the tibial shaft after reaming with those of nailing without reaming.

Study Design: This was follow-up comparative study.

Place and Duration of Study: This study was conducted at the Department of Orthopaedic, Shaikh Zayed Hospital, Lahore from Jan. 2009 to Dec. 2011.

Materials and Methods: Thirty patients who had thirty-four open fractures of the tibial shaft were randomized into two treatment groups. Sixteen fractures (nine type-I, three type-II, two type-IIIA, and two type-IIIB fractures, according to the classification of Gustilo et al.) were treated with nailing after reaming, and eighteen fractures (ten type-I, four type-II, two type-IIIA, and two type-IIIB fractures) were treated with nailing without reaming.

Result: The average diameter of the nail was 10 millimeters (range, nine to eleven millimeters) in the group treated with reaming and 9 millimeters (range, eight to ten millimeters) in the group treated without reaming. No clinically important differences were found between the two groups with regard to the technical aspects of the procedure or the rate of early postoperative complications. The average time to union was 30 weeks (range, thirteen to seventy-two weeks) in the group treated with reaming and 29 weeks (range, thirteen to fifty weeks) in the group treated without reaming. Two of the fractures treated with reaming and three of the fractures treated without reaming did not unite. There were two infections in the group treated with reaming and one in the group treated without reaming. More screws broke in the group treated without reaming four, per cent) than in the group treated with reaming (Three; 9 per cent). The functional outcome, in terms of pain in the knee, range of motion, return to work, and recreational activity, did not differ significantly between the groups.

Conclusion: We concluded that the clinical and radiographic results of nailing after reaming are similar to those of nailing without reaming for fixation of open fractures of the tibial shaft, although more screws broke when reaming had not been done.

Key Words: Intramedullary Nailing, Open Fractures, Tibial Shaft.

INTRODUCTION

Interlocking intramedullary nailing has become a popular method of fixation for closed tibial fractures, and a series of reports has confirmed excellent results with this technique^{1,2,3,4}. However, the use of intramedullary nails for open tibial fractures is controversial. The standard treatment for these injuries has been external fixation, particularly for fractures associated with more severe soft-tissue injuries^{5,6,7}.

Intramedullary nailing with reaming of the medullary canal is generally considered to be contraindicated for open fractures of the tibia^{8,9,10}, as the damage to the endosteal blood supply caused by reaming¹¹ may theoretically increase the risks of non-union and deep infection. It has, therefore, been suggested that insertion of nails without reaming is safer. Recent studies have indicated, however, that nailing either with or without reaming can be used for open tibial fractures with acceptable results^{12,13,14}. The purpose of the present

study was to compare the clinical and radiographic results of intramedullary nailing of open fractures of the tibial shaft after reaming with those of nailing without reaming.

MATERIALS AND METHODS

All grades of open injury were considered suitable for the study. The patients were randomized either nailing with reaming or nailing without reaming. Patients were excluded if they had a fracture in the proximal fourth of the tibia or a fracture within four centimeters of the ankle, neither of which was judged to be amenable to intramedullary nailing; if they had initially been managed with external fixation at another institution; or if they had open growth plates. There were no other exclusion criteria.

Thirty patients 34 with open fractures of the tibial shaft were entered into the study. Fifteen patients (16 fractures) were randomized to have a nail inserted after reaming, and 15 patients (18 fractures) were

randomized to have a nail inserted without reaming.

The degree of comminution was graded with use of the classification of Winkist and Hansen¹⁵. Two uncomminuted, twelve grade-I, ten grade-II, six grade-III, and four grade-IV fractures were treated. Two fractures involved the proximal third of the tibia; two, the proximal and middle thirds; eighteen, the middle third; ten, the middle and distal thirds; two, the distal third. The levels of the fractures, the degrees of comminution, and the patterns of the fractures were evenly distributed between the two groups. The severity of the open injury was determined with use of the classification of Gustilo et al^{16,17}, on the basis of the initial appearance of the wound and the findings during débridement. No type-IIIC open fractures of the tibial shaft were treated.

After the initial clinical assessment, all patients began receiving one gram of cefazolin intravenously every eight hours and were given prophylaxis against tetanus, if necessary. Patients who had a grade-III fracture¹⁵ were also given gentamicin intravenously (three to five milligrams per kilogram of body weight every twenty-four hours in three divided doses). Antibiotic therapy was maintained postoperatively for seventy-two hours. The same antibiotic regimen was used at each subsequent operative intervention. A standard operative protocol was followed. Wound débridement and nailing were performed as soon as possible after admission to the hospital. As part of the débridement protocol, a minimum of ten liters of saline solution was used for irrigation.

After débridement, nailing was performed with the patient on a fracture table using standard technique. Three nails were dynamized, one without reaming group and two with reaming group.

The average diameter of the nail was 10 millimeters in the group treated with reaming and 9 millimeters in the group treated without reaming.

No wound was closed primarily. The median time to coverage of the wound was five days for both groups. Split-thickness skin-grafting was performed for nine fractures. Ten wounds were treated with delayed primary closure. One fasciocutaneous flap, two gastrocnemius or soleus flaps were used for the type-IIIB injuries.

Early perioperative complications, including compartment syndrome, fat embolism, and pulmonary embolism, were recorded. Patients who had an isolated tibial fracture were discharged from the hospital when they had evidence of satisfactory wound-healing and were able to walk with crutches. Patients in both groups were advised to remain non-weight-bearing for the first six weeks after the injury, irrespective of the fracture configuration. Patients who had multiple injuries were mobilized and discharged as soon as the other injuries allowed it.

After discharge, we attempted to examine the patients

clinically and radiographically on a monthly basis until union. Clinical union was defined as the ability to bear full weight with no pain at the site of the fracture, and radiographic union was defined as evidence of bridging of three of the four cortices on standard anteroposterior and lateral radiographs. Fractures that needed revision intramedullary nailing or bone-grafting in order to heal were designated as non-unions. Fractures for which elective bone-grafting was used to bridge segmental defects after wound-healing were not considered non-unions unless subsequent operative intervention was necessary to achieve union. The fracture was converted to a dynamic status with removal of the proximal or distal locking screws at the discretion of the treating surgeon, and this was not taken to be an indication of non-union unless the fracture subsequently failed to heal. Six fractures that had been treated with reaming and four fractures that had been treated without it were converted to a dynamic status.

Malunion was defined as any angulation of more than 5 degrees in any direction as seen on the radiographs or shortening of more than one centimeter or rotation deformity of more than 15 degrees on clinical measurement. Failure of the implant and any action necessary as a result were recorded. A soft-tissue infection was defined as the presence of purulent discharge from the wound with positive bacteriological findings. Deep infection was diagnosed if operative exploration with osseous débridement was needed to eradicate the infection.

The ranges of motion of the knee and ankle were recorded for each patient. Motion of the subtalar joint was compared with that on the contralateral, normal side and was designated as normal or reduced at the time of the most recent follow-up examination.

The average duration of follow-up was 25 months (range, fourteen to fifty-four months). Ten patients (eleven fractures) who had had reaming and eleven patients (twelve fractures) who had not were followed by telephone and by contact with the local orthopaedic surgeon who was supervising the follow-up care. The prevalence of non-union, malunion, deep infection, and compartment syndrome were compared between the groups.

Statistical analysis: The data were analyzed using SPSS; descriptive analysis was done for both continuous and categorical variable.

RESULTS

The average age of the 20 male and 10 female patients was 27 years (range, sixteen to sixty years) (Fig. 1). Ten patients had been struck by a motor vehicle as a pedestrian, 5 were involved in a motor-vehicle accident as either the driver or a passenger, 11 were in a motorcycle accident, 2 were in a bicycle accident, and 2 had sustained the fracture as the result of a fall. These

patients stayed in the hospital for a median of seven days (range, four to thirty-eight days) when the nailing had been done after reaming and a median of eight days (range, four to twenty-nine days) when it had been done without reaming.

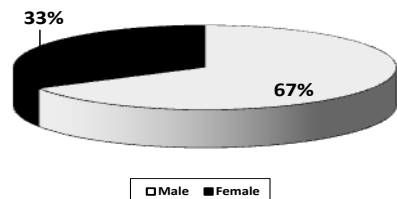


Figure No. 1: Gender distribution.

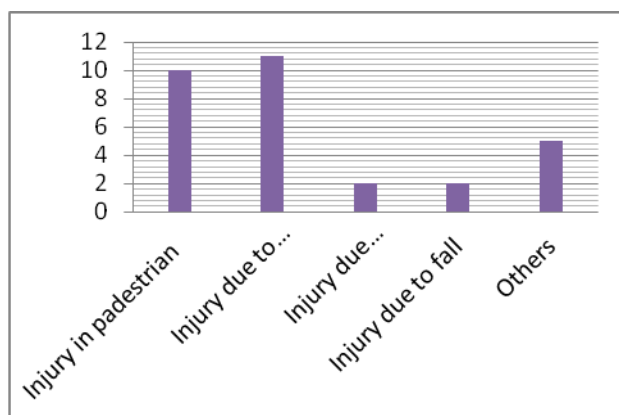


Figure No.2: Graph showing causes of injuries

Technical details: Few differences were noted between the two methods of nailing with regard to the technical details. With the numbers available, there were no significant differences between the two groups with regard to the average estimated blood loss or the average times needed for insertion of the nail, distal locking, and fluoroscopy. The average time needed for proximal locking was 10 minutes with or without reaming.

Early postoperative complications: A compartment syndrome developed in the injured limb of one patient who had had reaming. One patient who had not reaming had pulmonary emboli. Similarly, one patient who had had reaming had fat-embolism syndrome.

Union of the fracture: The average time to union was twenty-eight and twenty-one weeks for the type-I fractures in the group treated with reaming and the group treated without reaming, respectively; twenty-eight and twenty-seven weeks for the type-II fractures; thirty-four and thirty-one weeks for the type-IIIa fractures; and thirty and thirty-five weeks for the type-IIIb fractures. With the numbers available for study, the

observed differences were not significant.

Total were five cases, two fractures with reaming, three fractures without reaming.

Infection: There were two infections: one in the group that was treated with reaming and one, in the group that was treated without reaming. The patient in the group treated without reaming, who had a type-II open fracture, was seen six weeks after the injury at another hospital because of cellulitis around the fracture wound and a purulent discharge, which was determined to contain *Staphylococcus aureus* on culture. The patient was managed with intravenous administration of cloxacillin and the application of dressings. The infection resolved, and the patient was subsequently discharged. One deep infection in the group treated with reaming developed in a type-IIIb open fracture had been fixed with the use of a ten-millimeter-diameter nail. Four weeks later, the patient was seen with an abscess under the flap that communicated with the site of the fracture. Radiographs revealed that the nail had broken at the site of the fracture. The abscess was drained, the site of the fracture and the soft tissues were debrided of infected material. An antibiotic-bead werea implanted, and the wound was closed at five days. Bacteriological cultures were positive for *Staphylococcus aureus*, and the patient was managed with cloxacillin administered intravenously for fourteen days and then orally for an additional three months, by which time the fracture had healed with no sign of infection. One year after presentation of the infection, there had been no recurrence.

Failure of the implant: Breakage of a screw was associated with two nails that had been inserted after reaming and five nails that had been inserted without reaming. Two of these breakages were associated with a non-union, and none resulted in the development of a malunion. No specific action was taken, and the breakages did not compromise the outcome. Two of the nails that had been inserted after reaming broke: one breakage was associated with a deep infection, as already described, and one was associated with an aseptic non-union. One of the nails that had been inserted without reaming broke; this breakage was associated with a non-union. With the numbers available, the rates of broken nails were not significantly different between the two groups.

Malunion: There was a malunion of one of the fractures treated with reaming and one of the fractures treated without it, but the malunions were not related to failure of the implant.

Functional outcome: Three patients who had had reaming had a reduced range of motion of the knee. Two of these patients had had a severe injury of the ipsilateral femur (a comminuted grade-IIIa open fracture of the femoral shaft in one and a grade-IIIa

open supracondylar fracture in the other). One patient from the group treated without reaming, who had had a grade-IIIB tibial fracture with a ligamentous injury of the ipsilateral knee, also had a reduced range of motion of the knee.

Seven patients in the reamed group and six in the unreamed group had pain in the knee.

DISCUSSION

Intramedullary nailing after reaming is now accepted as the method of choice to treat open femoral fractures^{18,19,20}, but its use remains controversial with regard to open tibial fractures. The vascular damage inflicted by reaming in association with the soft-tissue injury has been thought to increase the risk of infection and delayed union to an unacceptable level²¹. Early reports of the use of unlocked nails with reaming for open tibial fractures seemed to confirm this view. Hamza et al²² reported three infections after the treatment of twenty-two open fractures, and Smith²⁸ subsequently reported six infections in eighteen patients. Recent authors have also been circumspect in their enthusiasm for the technique. Klemm and Börner reported six infections after treatment of ninety-three grade-I open fractures with insertion of a locking nail after reaming²³. Bone and Johnson reported two infections after treatment of eight grade-II and III fractures with nailing after reaming²⁴. On the basis of these studies, the current opinion is that insertion of a nail after reaming is contraindicated for the treatment of open tibial fractures^{8,9,10}.

The criticism that nailing after reaming is associated with high rates of infection and non-union is theoretical and is based on limited reports with small numbers of patients managed mostly with unlocked nails^{24,22}. Kaltenecker et al. reported no infections after treatment of sixty-six type-I and II open tibial fractures with nailing after reaming²⁵. Court-Brown et al. recently reported a rate of infection of 6 per cent (one of eighteen) for type-IIIA fractures and 13 per cent (three of twenty-four) for type-IIIB fractures treated with insertion of a Grosse-Kempf nail after reaming^{12,13}. Rates of union and malunion compared very favorably with those reported with current designs of external fixation^{5,6}.

Locking nailing without reaming causes less damage to the intramedullary blood supply and is considered by some to be a safer method of treatment for open tibial fractures^{26,27,28}.

We attempted to determine if the process of reaming was related to the rate of clinical complications. We did not find clear differences between our two groups. We did not demonstrate any clinically important differences with regard to the technical aspects of the operative procedure, and the rates of early complications were similar in the two groups. The over-all time to union and the rate of non-union were remarkably similar between the two groups, with no evidence that the reaming process delayed union. The need for bone-grafting was also rare; non-unions were treated successfully with revision of the nail.

We were unable to show that the reaming process is

associated with an increased risk of either deep infection or non-union. A recent experimental study revealed no difference in the mechanical strength of callus at three months when nailing after reaming was compared with nailing without reaming in a sheep model²⁸. Schemitsch et al. also showed a rapid recovery of blood flow to the site of the fracture despite reaming²⁸. The more important factor in fracture-healing and in the body's ability to resist infection is the viability of the surrounding soft tissue. Operative care of the soft-tissue wound is critical in the treatment of open fractures. The pluripotential mesenchymal cells that form fibrous tissue and eventually bone are thought to originate predominantly from surrounding tissue and the cambial layer of the periosteum. The reaming process is likely to have little detrimental effect on this aspect of fracture-healing. The role of the endosteal circulation in fracture-healing may therefore be less critical than has been supposed.

We believe that adequate débridement of the soft tissue and bone followed by sound soft-tissue coverage is the key to minimizing deep infection after these injuries, irrespective of whether the bone is reamed or not. The rate of infection in this series is lower than has been reported by others^{12,13}. This may be explained in part by our use of an antibiotic-bead pouch in the open wound. There is a gradually accumulating body of clinical evidence to suggest that this technique can help to decrease the prevalence of wound infection after open fractures²⁹.

The increased prevalence of failure of the locking screws in association with nails inserted without reaming has been noted by other authors¹⁴ but was not associated with an increased risk of non-union or malunion. As might be anticipated, the functional outcomes in the two groups were broadly similar in the present study.

Although this is the largest prospective trial of which we are aware, the number of patients in each group may not be large enough to demonstrate differences of small magnitude. On the basis of the results in this study, it seems likely that any relative advantage associated with either nailing after reaming or nailing without reaming is small and may only emerge in a study of much larger numbers of patients.

CONCLUSION

No comparable difference in outcome for open fractures tibial shaft treated with Intramedullary Locking. Nail with or without reaming noted.

REFERENCES

1. Court-Brown CM, Christie J, [McQueen MM. Closed intramedullary tibial nailing. Its use in closed and type I open fractures. *J Bone and Joint Surg* 1990;72-B(4): 605-11.
2. Ekeland A, Thoresen BO, Alho A, Strömsöe K, Follerås G, Haukebø A. Interlocking intramedullary nailing in the treatment of tibial fractures. A report of 45 cases. *Clin Orthop* 1988; 231: 205-15.

3. Klemm KW, Börner, M. Interlocking nailing of complex fractures of the femur and tibia. Clin Orthop 1986; 212: 89-100.
4. Puno RM, Teynor JT, Nagano J, Gustilo RB. Critical analysis of results of treatment of 201 tibial shaft fractures. Clin Orthop 1986; 212: 113-21.
5. De Bastiani G, Aldegheri R, Brivio LR. The treatment of fractures with a dynamic axial fixator. J Bone and Joint Surg 1984; 66-B(4): 538-45.
6. Edwards CC. Staged reconstruction of complex open tibial fractures using Hoffmann external fixation. Clinical decisions and dilemmas. Clin Orthop 1983;178: 130-61.
7. Lawyer RB, Lubbers LM. Use of the Hoffmann apparatus in the treatment of unstable tibial fractures. J Bone and Joint Surg 1980;62-A: 1264-73.
8. Brumback RJ. Open tibial fractures: current orthopaedic management. In Instructional Course Lectures, The American Academy of Orthopaedic Surgeons. Vol. 41, pp. 101-117. Park Ridge, Illinois, The American Academy of Orthopaedic Surgeons 1992.
9. Gustilo RB, Merkow RL, Templeman D. Current concepts review. The management of open fractures. J Bone and Joint Surg 1990; 72-A: 299-304.
10. Sanders R, Swiontkowski M, Nunley, J, Spiegel P. The management of fractures with soft-tissue disruptions. J Bone and Joint Surg 1993;75-A: 778-89.
11. Rhinelander FW. Tibial blood supply in relation to fracture healing. Clin Orthop 1974; 105: 34-81.
12. Court-Brown CM, Keating JF, and McQueen MM. Infection after intramedullary nailing of the tibia. Incidence and protocol for management. J Bone and Joint Surg 1992; 74-B(5): 770-74.
13. Court-Brown CM, McQueen MM, Quaba AA, Christie J Locked intramedullary nailing of open tibial fractures. J Bone and Joint Surg 1991;73-B(6): 959-64.
14. Whittle AP, Russell TA, Taylor JC, Lavelle DG. Treatment of open fractures of the tibial shaft with the use of interlocking nailing without reaming. J Bone and Joint Surg 1992; 74-A: 1162-71.
15. Winquist RA, Hansen ST. Comminuted fractures of the femoral shaft treated by intramedullary nailing. Orthop Clin North Am 1980;11: 633-48.
16. Gustilo RB, Anderson JT. Prevention of infection in the treatment of one thousand and twenty-five open fractures of long bones. Retrospective and prospective analyses. J Bone and Joint Surg 1976; 58-A: 453-58.
17. Gustilo RB, Mendoza RM, Williams DN. Problems in the management of type III (severe) open fractures: a new classification of type III open fractures. J Trauma 1984;24:742-46.
18. Brumback RJ, Ellison PS, Poka A, Lakatos R, Bathon GH, Burgess AR. Intramedullary nailing of open fractures of the femoral shaft. J Bone and Joint Surg 1989;71-A: 1324-31.
19. Lhowe DW, Hansen ST. Immediate nailing of open fractures of the femoral shaft. J Bone and Joint Surg 1988; 70-A: 812-20.
20. O'Brien PJ, Meek RN, Powell JN, Blachut PA. Primary intramedullary nailing of open femoral shaft fractures. J Trauma 1991;31:113-16.
21. Chapman MW. The role of intramedullary fixation in open fractures. Clin Orthop 1986; 212: 26-34.
22. Hamza KN, Dunkerley GE, Murray CMM. Fractures of the tibia. A report on fifty patients treated by intramedullary nailing. J Bone and Joint Surg 1971; 53-B(4): 696-700.
23. Smith JEM. Results of early and delayed internal fixation for tibial shaft fractures. A review of 470 fractures. J Bone and Joint Surg 1974; 56-B(3): 469-77.
24. Bone LB, Johnson KD. Treatment of tibial fractures by reaming and intramedullary nailing. J Bone and Joint Surg 1986; 68-A: 877-87.
25. Kaltenecker G, Wruhs O, Quaiocoe, S. Lower infection rate after interlocking nailing in open fractures of femur and tibia. J Trauma 1990;30: 474-79.
26. Kessler SB, Hallfeldt KJ, Perren SM, Schweiberer L. The effects of reaming and intramedullary nailing on fracture healing. Clin Orthop 1986; 212: 18-25.
27. Klein MP, Rahn BA, Frigg R, Kessler S, Perren SM. Reaming versus non-reaming in medullary nailing: interference with cortical circulation of the canine tibia. Arch Orthop and Trauma Surg 1990; 109: 314-16.
28. Schemitsch EH, Kowalski MJ, Swiontkowski MF, Harrington RM, Senft D. Effects of reamed versus unreamed locked nailing on callus blood flow and early strength of union in a fractured sheep tibia model. Orthop Trans 1994; 18: 145.
29. Henry SL, Ostermann PA, Seligson, D. The prophylactic use of antibiotic impregnated beads in open fractures. J Trauma 1990; ,30: 1231-38.

Address for Corresponding Author:**Dr. Naveed Ishaq Malik**

Assistant Professor

Orthopaedic Deptt CMH, Lahore

Email malik_ni@yahoo.com

Mob 03214523241