

# Role of MDCT in Diagnosis of Fungal Sinusitis

1. Ambreen Sair 2. Arfan-ul-Haq 3. Asma Tariq

1. Resident Radiologist, PNS Shifa (Neval Hospital), Karachi 2. Radiologist, AFIRI, Rawalpindi  
3. Radiologist, CHH, Lahore

## ABSTRACT

**Objective:** To evaluate diagnostic accuracy of MDCT in diagnosis of fungal sinusitis.

**Study Design:** Cross sectional study.

**Place and Duration of study:** This study was conducted at the Department of Radiology PNS SHIFA Hospital Karachi from 18th April 2012 to 17th October 2012.

**Materials and Methods:** 126 patients of all ages and gender with clinical suspicion of fungal sinusitis were included in the study. Non-contrast enhanced axial and coronal CT performed on 16slice MDCT. 76% patients were male, 24% female, 98.4% were immunocompetent and 1.6% were immunocompromised. CT finding of mucosal thickening with hyper-attenuating areas in effected sinuses was considered CT diagnostic criteria for fungal sinusitis. Biopsy and histopathology performed in every case and histopathological diagnosis was considered as 'Gold standard' for comparison of CT findings. Findings of every patient were recorded on a specially designed Performa. SPSS version 10 used to calculate diagnostic accuracy of MDCT in fungal sinusitis.

**Results:** 32 (25.4%) patients showed mucosal thickening with internal hyper-attenuating areas in the sinuses representing fungal rhinosinusitis. Results compared with biopsy reports. The sensitivity, specificity, positive predictive value, negative predictive value and accuracy of CT scan in detection of fungal sinusitis were 100%, 93%, 78%, 100% and 94%. 5 (4%) patients showed intraorbital extension and 3 (2.4%) patients showed both intraorbital and intracranial extension of disease.

**Conclusion:** MDCT is very useful and accurate in diagnosis of fungal sinusitis. It should be considered as first investigation of choice to confirm or to rule out fungal sinusitis in clinically suspected patients. MRI should supplement MDCT in those cases of fungal sinusitis in which intraorbital or intracranial extension of disease is suspected.

**Key Words:** MDCT, Fungal sinusitis, hyper-attenuating areas in sinuses.

## INTRODUCTION

Fungal sinusitis is a relatively common but often misdiagnosed disease process involving the para-nasal sinuses. It is a serious condition as certain forms of fungal sinusitis are associated with a high rate of mortality<sup>1</sup>. Over the last two decades the incidence of fungal sinusitis has increased dramatically<sup>2</sup>. Successful treatment requires a prompt diagnosis and frequently relies upon radiologic imaging, specifically computed tomography and magnetic resonance imaging<sup>3</sup>. Now a days MRI is considered the imaging modality of choice for evaluation of suspected fungal sinusitis and has high accuracy in its detection and characterization<sup>4</sup>. Availability and its cost is a limiting factor for MRI. Multi-slice computed tomography (MDCT) is more easily available. So we conducted a study to see the sensitivity and specificity of MDCT in diagnosis of fungal sinusitis.

## MATERIALS AND METHODS

This Cross sectional study was conducted at the Department of Diagnostic Radiology, PNS SHIFA Naval Hospital, Karachi from 6 months, 18th April 2012 to 17th October 2012.

**Sample Size:** 126 patients

**Sampling Technique:** Non-probability purposive sampling

**Sample Selection Inclusion Criteria:** Patients of all age groups and gender, with suspicion of fungal rhinosinusitis presenting with all or any two of the following were included in study:

- Nasal obstruction with nasal discharge and Postnasal drip
- Chronic rhinosinusitis resistant to routine treatment
- Sinusitis with suspected intracranial extension
- Sinusitis with suspected intraorbital extension
- Sclerosis of sinus walls seen on plain x-ray in snusitis patients

Note: Already diagnosed cases of fungal sinusitis were not included in study.

**Data Collection Procedure:** All patients were explained Purpose & procedure of study including the risks & benefits. After taking informed consent from patients study proforma were filled. Approval from ethical committee of the institute, PNS SHIFA hospital, was also taken. Computed Tomography performed on **Toshiba Aquilion 16 Multi-detector CT (MDCT)** scanner. Non contrast enhanced CT was performed every patient in axial and coronal planes with scanning protocol of section thickness 3mm, collimation 3mm, reconstruction interval 3mm, mAs 140 and KV 120.

Scanning in every patient was done from hard palate to the top of the frontal sinuses. The image interpretation of the lesions in every case was done by a consultant radiologist having minimum 3 years of post FCPS experience. CT findings of every patient, regardless of scan result suggestive of either presence or absence of fungal rhino-sinusitis, were recorded on the proforma and histopathological finding of each patient whether positive or negative for fungal sinusitis were collected and documented on proforma.

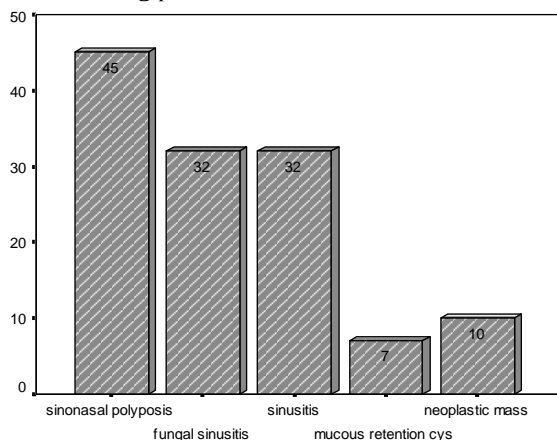
**Data Analysis Procedure:** Data was analyzed on SPSS version 10. Sensitivity, specificity, positive predictive value, negative predictive value and accuracy of MDCT in detecting fungal rhino-sinusitis was calculated by considering histopathological findings as “gold standard”.

Stratification was done with regards to age, gender and duration of symptoms to see the effects of these factors in CT diagnosis.

## RESULTS

126 patients with suspected fungal rhinosinusitis, included in the study, were between 21 to 60 years of age. Out of 126 patients, 96 (76%) were male and 30 (24%) were female. 124 (98.4%) patients were immunocompetent and 2 (1.6%) were immune-compromised.

Out of 126 patients, 32 (25.4%) patients showed mucosal thickening and soft tissue areas with internal hyper-attenuating areas with calcifications in the sinuses representing fungal rhinosinusitis. Other 32 (25.4%) patients showed only mucosal thickening without hyper-attenuating areas consistent with simple chronic sinusitis. 7 (5.6%) patients showed mucous retention cyst. 10 (7.9%) patients showed neoplastic lesions involving para-nasal sinuses.



**Figure-1: Graph showing CT Scan Diagnosis of Paranasal Sinuses Lesions (n = 126)**

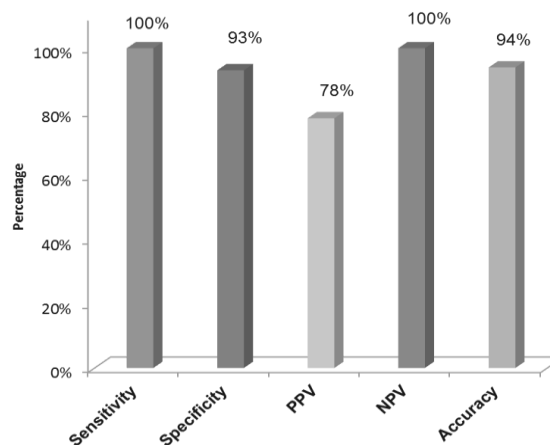
True positive and negative outcome of CT scan and histopathology in detection of fungal infections of paranasal sinuses is presented in the table-1 appended below:

**Table No.1: True positive and negative outcome of CT scan and histopathology in detection fungal infections in our study.**

Computed Tomography Findings	Histopathological		Total
	Positive	Negative	
Positive	25 (TP)	7 (FP)	32(25.4%)
Negative	0 (FN)	94 (TN)	94(74.6%)
Total	25(19.8%)	101(80.2%)	126

The sensitivity, specificity, positive predictive value, negative predictive value and accuracy of CT scan in detection of fungal infections of paranasal sinuses were 100%, 93%, 78%, 100% and 94% respectively as shown in figure below.

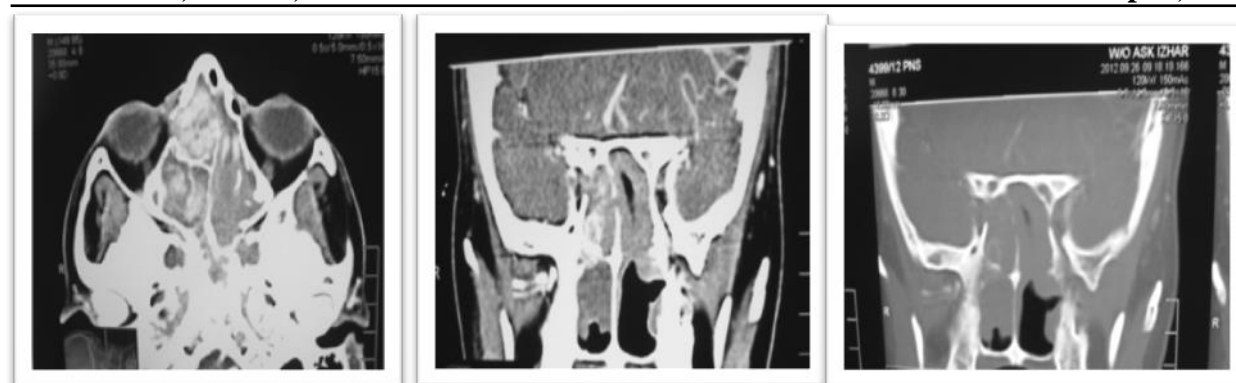5 (4%) patients showed intraorbital extension and 3 (2.4%) patients showed both intraorbital and intracranial extension of disease which was later confirmed on MRI during further management.



**Figure No. 2: Diagnostic accuracy of CT scan in detection of fungal infections of para-nasal sinuses (n=126)**

## DISCUSSION

CT scan, with its inherent high contrast resolution, allows for excellent demonstration of bony architecture, air in the sinuses and soft tissue masses in paranasal sinuses and nasal cavity. CT scan should thus be superior to plain radiography in demonstrating fine areas of increased attenuation in soft tissue masses<sup>5</sup>. CT is the imaging study of choice in both adult and pediatric patients<sup>6</sup>. On plain X-Ray presence of bony sclerosis along with mucosal thickening is considered important in suspecting diagnosis of fungal sinusitis<sup>7</sup> whereas on CT presence of hyper-attenuating areas in sinuses is considered diagnostic of fungal sinusitis<sup>8</sup>. With fungal sinusitis, the maxillary and ethmoid sinuses are most commonly involved. Allergic fungal sinusitis can involve complete opacification of multiple paranasal sinuses, unilateral or bilateral; sinus expansion and erosion of a wall of the involved sinus; and high-attenuating areas scattered amid mucosal thickening on nonenhanced scans.



**Fig No.3: Fungal sinusitis showing hyperdense areas in sinuses and bone erosion**

These areas are due to inspissated secretions or heavy metals, such as iron, manganese, and calcium<sup>9,10</sup>. In our study out of 32 patients of fungal sinusitis, bony sclerosis was noted only in 8 patients (25%) on plain X-Ray whereas on CT internal hyper-attenuating areas with calcifications representing fungal rhinosinusitis was present in 25 out of 32 patients (78%). Vartanian and Meyers in 2012 noted hyperattenuating areas on CT in fungal sinusitis in 81%.<sup>11</sup> Intrasinus calcification on CT with aspergillosis is a characteristic feature of fungal sinusitis and is present in 69–77% of cases<sup>12</sup>. Hyperattenuating areas are due to calcium and magnesium salts deposited in the necrotic areas of the mycelia and fungus-infected mucin<sup>13</sup>. Calcification may occur with other pathologic processes, such as bacterial sinusitis, mucocoeles, and neoplasms, but it is uncommon in nonfungal inflammatory sinonasal disease<sup>14</sup>. Intrasinus calcification on CT with aspergillosis is a characteristic feature of fungal sinusitis and is present in 69–77% of cases<sup>13</sup>. The shape and location of calcification in nonfungal cases are different from those of fungal sinusitis. Calcification in fungal cases is primarily centrally located in the maxillary antrum, whereas the calcification in nonfungal cases is usually peripheral, near the wall of the maxillary sinus. Fine punctuate calcification has been identified only in fungal sinusitis, although smooth, marginated, round, or eggshell calcification has been found exclusively with non-fungal disease<sup>15</sup>. So, presence of hyper-attenuating areas or calcification in sinuses on CT is an important diagnostic feature of fungal sinusitis. Pattern and location of calcification in the sinus should also be considered while making the diagnosis of fungal sinusitis and ruling out other causes of calcification in sinuses.

Other noteworthy CT features of fungal sinusitis are reactive changes in bones of sinus wall and infiltration of adjacent soft tissue with bone destruction in the case of invasive fungal sinusitis<sup>16</sup>. CT is very sensitive for early detection of bone erosion. CT is the primary imaging modality and is probably more accurate than MRI in diagnostic specificity and determining the extent of bone erosion<sup>17</sup>. In this study, erosions of lamina papyracea was noted in 28 patients (87%) out of

32 patients of fungal sinusitis. Del Gaudio in a study in 2003 found bone destruction / erosion in 71 % of his patients of invasive fungal sinusitis<sup>8</sup>. Difference is due to stage and severity of disease process and pattern of sinus involvement. Bone destruction is common in advanced disease and when there is involvement of ethmoid sinuses<sup>18</sup>. In 1998, Silverman and his colleagues described soft tissue changes in the sinus with thickened reactive bone inflammation or with associated nasal inflammation as an early predictor of fungal disease<sup>16</sup>. Ramadan H and his colleagues in a study carried out on management of fungal sinusitis in 2011 found CT as an extremely useful diagnostic modality in detection of intracranial and intraorbital extension of disease process, an important factor in treatment planning.<sup>19</sup>

In many institutions, a limited CT scan costs about the same as a full radiographic series but provides more useful information<sup>20,21,22</sup>. Multiplanar reconstruction of images that is in axial, coronal and sagittal planes and viewing scans at both soft tissue and bone window levels was found very useful to depict and localize hyper-attenuating areas in sinuses and to detect bone erosion. It is recommended by others in their studies as well<sup>18</sup>. A noncontrast CT scan is usually sufficient, except for complicated acute sinusitis (e.g., periorbital cellulitis or abscess). We did not find any difference in CT appearance of fungal sinusitis with reference to age and sex of the patient. However disease was more aggressive in two immunocompromised patients and bone erosion was more common when ethmoid sinuses were involved which may be attributed to their small size and thin walls.

One limitation in our study was that we did not give IV contrast in these patients due to whom we felt difficulty in the differentiation of mucosal thickening from pus-filled areas of sinuses and in interpreting intraorbital and intracranial extension of disease.

## CONCLUSION

CT, now commonly available radiological modality, is most practical primary imaging modality for suspected fungal disease of the para nasal sinuses. It has very high diagnostic sensitivity, specificity, positive predictive

value, negative predictive value and accuracy in detection of fungal sinusitis in the range of 100%, 93%, 78%, 100% and 94% respectively. It is probably more accurate than MRI in terms of defining degree and extent of bone erosion, whereas MRI is more sensitive to detect early inflammatory changes in intraorbital or intracranial soft tissues. While doing the CT in addition to routine axial scanning direct coronal scans should be obtained and IV contrast should be given in every patient. MRI should be used to supplement CT to further evaluate the extent and pattern of involvement of soft tissue structures once intracranial or intraorbital disease extension is suspected on CT.

## REFERENCES

1. Mafee MF. Imaging of paranasal sinuses and rhinosinusitis. *Clin Allergy Immunol* 2007;20: 185-226.
2. Mc Clay JE, Marple B, Kapadia L Biavati MJ et al. Clinical Presentation of Allergic Fungal Sinusitis in Children. *Laryngoscope* 2002; 112: 565-69.
3. Zinreich SJ. Progress in sinonasal imaging. *Ann Otol Rhinol Laryngol* 2006 Suppl;196:61-5.
4. Momeni AK, Roberts CC, Chew FS. Imaging of chronic and exotic sinonasal disease: review. *AJR Am J Roentgenol* 2007;189(6 Suppl):S35-45.
5. Zinreich JS, Kennedy W, Malat Jan, Curtin D. Fungal Sinusitis: Diagnosis with CT and MR imaging. *Head and Neck Radiol* 1988;169:439-44.
6. Kronemer KA, McAlister WH. Sinusitis and its imaging in the pediatric population. *Pediatr Radiol* 1997;27:837-846.
7. Aribandi M, McCoy VA, Bazan C 3rd. Imaging features of invasive and noninvasive fungal sinusitis: a review. *Radiographics* 2007;27(5): 1283-96.
8. DelGaudio JM, Swain RE Jr, Kingdom TT, Muller S, Hudgins PA. Computed tomographic findings in patients with invasive fungal sinusitis. *Arch Otolaryngol Head Neck Surg* 2003;129(2): 236-240.
9. Shah A. Allergic bronchopulmonary and sinus aspergillosis: the roentgenologic spectrum. *Front Biosci* 2003;8:E138-46.
10. Dhiwakar M, Thakar A, Bahadur S. Preoperative diagnosis of allergic fungal sinusitis. *Laryngoscope* 2003;113(4):688-94.
11. Vartanian A, Meyers D. CT Scan of the Paranasal Sinuses. Updated: Oct 8, 2012 <http://emedicine.medscape.com/article/875244-overview>.
12. Bhattacharyya N, Fried MP. The accuracy of computed tomography in the diagnosis of chronic rhinosinusitis. *Laryngoscope* 2003;113(1):125-9.
13. Yoon JH, Na DG, Byun HS, Koh YH, Chung SK, Dong HJ. Calcification in chronic maxillary sinusitis: comparison of CT findings with histopathologic results. *AJNR* 1999;20:571-74.
14. Som RM, Lidov M. The significance of sinonasal radiodensities: ossification, calcification, or residual bone? *AJNR* 1994;15:917-22.
15. Schubert MS. Allergic fungal sinusitis. *Otolaryngol Clin North Am* 2004;37(2):301-326.
16. Silverman CS, Mancuso AA. Periantral soft-tissue infiltration and its relevance to the early detection of invasive fungal sinusitis: CT and MR findings. *AJNR Am J Neuroradiol* 1998;19(2):321-325.
17. Lund VJ, Lloyd G, Savy L, Howard D. Fungal rhinosinusitis. Institute of Laryngology & Otolaryngology, University College London, UK. *J Laryngol Otol* 2000;114(1):76-80.
18. Rochita V, Ramanan, L Gill Naul. Sinusitis Imaging. Medscape reference Updated: May 25, 2011.
19. Ramadan H, Meyers D. Fungal Sinusitis Treatment & Management <http://emedicine.medscape.com/article/863062>. Updated: Aug 19, 2011.
20. Poole MD. A focus on acute sinusitis in adults: changes in disease management. *Am J Med* 1999;106:38S-47S.
21. Kaliner M. Medical management of sinusitis. *Am J Med Sci* 1998;316:21-8.
22. Incaudo GA, Wooding LG. Diagnosis and treatment of acute and subacute sinusitis in children and adults. *Clin Rev Allergy Immunol* 1998;16:157-204.

### Address for Corresponding Author:

**Dr. Ambreen Sair,**  
Resident Radiologist,  
PNS Shifa (Neval Hospital), Karachi