

Rhomboid Flap in the Treatment of Pilonidal Sinus Disease

1. Zulfiqar Ali Shahid 2. Khalid Hussain Qureshi 3. Nabeel Ahmed

1.Asstt. Prof. 2.Assoc. Prof. 3.Surgical Resident, Department of Surgery, Nishtar Hospital Multan

ABSTRACT

Objective: The aim of our study was to present our experience with the Rhomboid flap technique in the management of pilonidal sinus disease and to evaluate the morbidity and recurrence.

Study Design: Cross-sectional, observational study.

Place and Duration of Study: This study was conducted in the surgical department of Nishtar Hospital Multan Ward 4 surgical unit I, October 2011 to March 2012.

Materials and Methods: Eleven patients were included, eight had previous surgical drainage of multiple natal cleft abscesses, and three had acute disease at the time of surgery. Nine patients had complex, recurrent pilonidal sinus. By using the Rhomboid transposition flap, we were able to excise the diseased area and close the defect. Operative time, hospital stay, healing time, wound infection, wound breakdown, return to normal activity and recurrence were assessed.

Results: There were 10 males and one female with a median age of 23 years (range 17–32 years). Mean follow-up was 6 months (range 5-6 months). Mean operative time was 63.2 minutes (range 55-75 minutes). Hospital stay was 3.4 days (range 2-5). Postoperative morbidity involved superficial wound infection in two patients, superficial gangrene of wound edges in one patient and partial wound breakdown in one patient that settled with dressing in the out-patient clinic. All wounds healed and the median healing time was 15 days. There was no recurrence in our series. Median time to return to normal activity was 17.8 (range 10-27) days.

Conclusion: Rhomboid flap is a useful technique in the treatment of advanced, difficult cases of pilonidal sinus disease. It has relatively low morbidity, allows early return to full activity and does not necessitate prolonged postoperative care. A larger series and longer follow up time is needed to assess the recurrence rate more adequately.

Key Words: Rhomboid flap technique, Pilonidal sinus disease.

INTRODUCTION

Pilonidal sinus disease is a painful and chronic condition affecting males predominantly and can lead to considerable discomfort and morbidity. It occurs in the intergluteal region and is the result of shed hair shafts through the skin, which ultimately leads to an acute or chronic infected site.(1)

In 1833, Mayo was the first to report a hair containing sinus and Hodges in 1880 suggested the term pilonidal sinus (Latin: *pilus* = hair and *nidus* = nest), to indicate a disease consisting of hair containing sinus in the sacrococcygeal area.(2) Buie(3) described the condition as jeep disease, because it is believed that it is caused by long periods of sitting in vehicles.

In 20% of cases, the disease is observed as an acute abscess, whereas in the remaining cases it presents as a chronic sinus, in which there are draining orifices.(4,5) Surgical drainage of pilonidal abscess can be used occasionally as a definitive treatment of small pilonidal sinus with abscess formation. However, advanced disease with multiple pilonidal sinus openings, branching tracts, and overt symptoms may require wide excision of the diseased region. The closure of the defect can be either by simple approximation of the edges or by using flaps.(6)

A simple excision and open wound healing cause more patient discomfort, longer hospitalization, require more time off work and requires regular outpatient dressing, whereas primary wound closure is associated with wound related complications, such as failure of primary wound healing and late pilonidal recurrence.

Thus, a large variety of flap techniques for covering the wound cavity were introduced.(4,6–8)

In this study we present our experience with one type of flap techniques for closure of the defect after excision of the pilonidal sinus, i.e. Rhomboid flap closure.

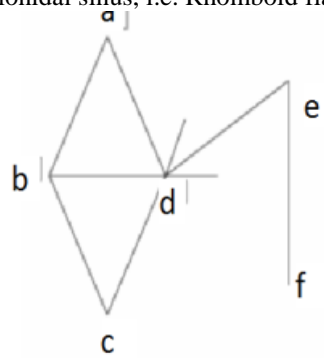


Figure No.1:

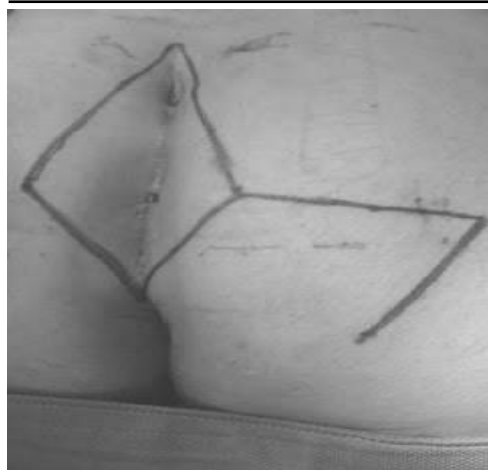

Figure No.2:

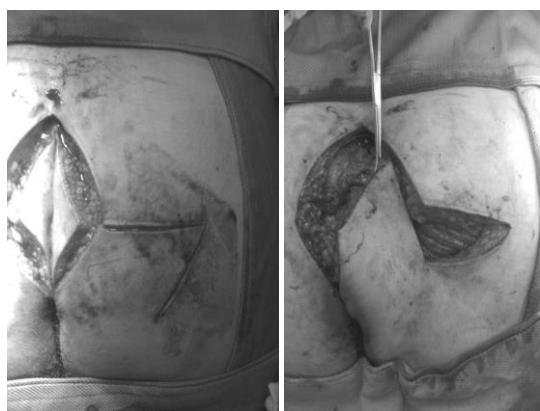


Figure No.3:

Figure No.4:

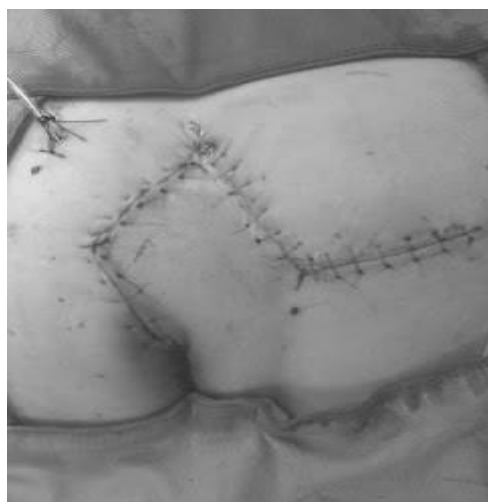


Figure No.5:

MATERIALS AND METHODS

This study was conducted in surgical unit- I Nishtar Hospital Multan, from october 2011 to March 2012.. Eleven patients underwent the procedure. None of them had a sedentary life. Eight patients had previous multiple abscess formation requiring surgical drainage

from their pilonidal disease and three had acute disease with pus discharge at the time of surgery. Nine patients had complex, recurrent pilonidal sinus. The procedure was explained to all patients and an informed consent obtained.

Preparation: All patients were admitted to the hospital one day before operation. All were operated on under general anaesthesia. A single dose of Ceftriaxone 1g was administered on induction of anaesthesia for prophylaxis against wound infection for all patients. were placed in the prone position, with buttocks strapped apart using adhesive bands. The sacrococcygeal area was shaved and cleaned using povidine-iodine. The extent of the sinuses was determined by inspection and palpation and all diseased areas were included in the incision.

Surgical Procedure: The area to be excised (abcd) is marked on the skin (Fig. 1) with the axis ac being along the natal cleft, with the anus below c. Lines cd and bd are then extended and the angle thus formed is bisected by lines having the same length as any one side of the rhomboid (thus $ab = bc = cd = ad = de$). Line ef is then drawn parallel to the long axis ac. The sinus (Fig. 2, 3) is excised down to the sacrococcygeal fascia centrally and the gluteal fascia laterally, and haemostasis is secured using diathermy. The rhomboid flap (Fig. 4,) is mobilized from the gluteal fascia and sutured without tension, with interrupted mattress sutures over a suction drain (Fig. 5). When there was an abscess, it was included with all diseased skin in the excised rhomboid.

Aftercare: After the operation, 500mg of Paracetamol and 50mg of Diclofenac Sodium were administered as soon as oral feeding was resumed for postoperative pain management for three days postoperatively. Patients were advised to lie on the lateral side until the wound healed. The dressing was changed on the second postoperative day, the drain is removed and the patients are usually discharged on the fourth day. The patients were advised on the importance of regular shaving of the buttocks and hygienic measures. The sutures were removed on the tenth postoperative day. Patients were followed up weekly for the first six weeks postoperatively, then monthly thereafter During each follow up session, bleeding, haematoma formation, infection, state of healing and recurrence were evaluated.

RESULTS

There were 10 males and one female with a mean age of 23 years (range 17–32 years). Clinical presentation included: local swelling (8 cases), pilonidal abscess (3 cases), and multiple sinuses with chronic suppurative discharge (9 cases) (see Table I). Mean operative time was 63.2 minutes (range 55-75 minutes). The duration of hospital stay was two to five days (mean 3.4 days). Primary healing occurred in nine patients when reviewed at the time of suture removal on the twelfth

day. One patient developed partial wound breakdown and one patient developed superficial gangrene of the wound edges, both were treated with dressings at the out-patient clinic. Postoperative complications were superficial wound infection in two patients, which needed daily dressing. All wounds healed, and the mean healing time was 15 days, range (12-21 days). None of the patients developed flap necrosis. Mean time to return to normal activity was 17.8 (range 10-27) days.

Mean time off work was 21.4 days. Mean follow-up time was 6 months (range 5-6 months).

Table No.1: Clinical manifestations

Clinical manifestation	Patients	Frequency (%)
Local swelling	8	73
Acute abscess	3	27
Chronic suppurative discharge	9	81

Table No.2: Summary of results of different therapeutic procedures

Technique	Hospital stay (days)	Healing time (days)	Infection rate	Recurrence%
Phenol application ⁽¹⁸⁾	0	-	-	8.3
Radiofrequency incision ⁽²⁵⁾	<1	42-75	0	0
Rhomboid flap ⁽²⁸⁾	3-10	14	0	7
Excision and marsupialization ⁽²³⁾	1.3	44.4	-	10
Excision and primary closure ⁽³⁵⁾	<1	12	2	6.3
Limberg flap ^(6,9,33)	5.6	-	0-23	4.7
V-Y flap ^(27,36)	3.5	-	0	0-5.9
Dufourmentel technique ⁽¹³⁾	4	14	0	0
Present series	3.4	15	2	0

DISCUSSION

Pilonidal sinus disease occurs in the sacrococcygeal region. Hirsuteness, moderate obesity, puberty, vacuum effect and deep intergluteal sulcus are all factors that contribute to the development of the disease.^{1,9,10} The incidence rate of pilonidal disease is approximately 700 per 100,000. The disease is found predominantly in whites; it is rare in blacks and practically nonexistent in Asians. It is now known that the pilonidal cyst is an acquired chronic disease of foreign body type caused by penetration of short, stiff hairs into the subcutaneous tissues.² Pilonidal sinus predominantly affects patients in their twenties and thirties and males more than females. In our series, age distribution was similar to that reported in the literature,^{7,11,12} but with male predominance. Male to female ratio was 10:1 while some authors reported a male to female ratio of 1:2.¹³ In this study, location of the pilonidal disease was in the natal cleft, nevertheless different locations for this condition have been described, including penis, axilla, perineal and suprapubic area, periumbilical zone, between the fingers of the hand (Barber's disease), and even in the ends of amputated extremities.^{14,15} In spite of high incidence of pilonidal disease affecting young population and the prolonged disabling period caused by it, surgeons have not reached unanimity about the best treatment for this condition. Low recurrence rate, minimal inpatient stay, minimal cost, minimal operation time, minimal inconvenience, and minimal time off work are important considerations. Nonsurgical and surgical techniques were proposed. Nonsurgical techniques have included: local hygiene and weekly shaving of the sacrococcygeal area,¹⁶ laser epilation of the intergluteal hair¹⁷ and phenolization of the sinus

tracts, but the later carries considerable risk of chemical burn and seroma formation.¹⁸ Several surgical techniques have been described to date: cutting section,¹⁹ cryosurgery,²⁰ aspiration followed by treatment with antibiotics, drainage with or without curettage,⁹ excision and primary closure,^{21,22} or excision and marsupialization,²³ vacuum assisted closure,²⁴ sinus excision and delayed closure.²⁵ Bascom *et al.*²⁶ reported that the most common cause of failure of healing after surgery is the deep cleft, moist and rolling action of the buttocks. Flattening the natal cleft was proposed to prevent the macerating action induced by rolling the buttocks while walking. Hence techniques which involved the obliteration of the deep natal cleft, such as Z-plasty⁴ V-Y advancement flap,²⁷ rhomboid flaps^{9,13,28} and primary skin grafting,²⁹ have been developed. Among these procedures, our treatment of choice is the rhomboid flap. We believe it is a very good plastic procedure for the treatment of pilonidal sinus however we try to use this technique only in cases of pilonidal sinus with multiple previous failed operations and when there is a large area which needs to be excised. A comparison of our results regarding hospital stay, healing time, infection rate and recurrence is similar to those reported in the literature (see Table II). Galala *et al.*³⁰ compared the rhomboid flap and the deep suturing techniques and showed higher healing rates and lower recurrence rate for the former. Our rates of healing and superficial wound infections are comparable to their findings. There is a high recurrence rate in most published series irrespective of the procedure.

Edwards³¹ has reported a 46% recurrence rate for excision and healing by secondary intention and a 38% recurrence rate is quoted for excision and primary closure. Others³² reported even higher recurrence rates

for those two techniques, whereas Manterola *et al.*¹³ in a study on 25 cases that were treated by rhomboid flap technique, reported zero recurrence rate after a mean of 3.4 years of followup. Other studies^{6,33,34} give a recurrence rate in the range of 2.5-4.8% for different periods of follow-up. We had no recurrence of the pilonidal sinus disease, but a longer follow up time will show the true results of this procedure. The reported average time lost from work was some 13 weeks of which 6-7 weeks were spent recovering from an operation designed to cure the condition.²⁸ In our study, the median time to return to normal activity was 17.8 days and off work time was 21.4 days. This is another advantage of this procedure, keeping in mind that more than 90% of our patients are working personnel.

CONCLUSION

Rhomboid flap is a technique used for the treatment of advanced, difficult cases of pilonidal sinus disease. The method is easy to use, has relatively low rate of wound infection, requires short wound healing time, does not need prolonged postoperative dressings, and allows early return to normal activities. A larger series and longer follow up is needed to give the true picture about the recurrence rates of pilonidal sinus following this procedure.

REFERENCES

1. Bascom J. Pilonidal Sinus. *Curr Ther Colon Rectal Surg* 1990; 1-8.
2. da Silva J. Pilonidal cyst: cause and treatment. *Dis Colon Rectum* 2000; 43: 1146-1156.
3. Buie L. Jeep disease, pilonidal disease of mechanized warfare. *South Med J* 1944;37: 103-109.
4. Fazeli M, Adel M, Lebaschi A. Comparison of Journal of The Royal Medical Services Vol. 17 No. 4 December 2010 39 outcomes in Z-plasty and delayed healing by secondary intention of the wound after excision of the sacral pilonidal sinus: results of a randomized, clinical trial. *Dis Colon Rectum* 2006; 49: 1831- 1836.
5. Petersen S, Koch R, Stelzner S, et al. Primary closure techniques in chronic pilonidal sinus. A survey of the results of different surgical approaches. *Dis Colon Rectum* 2002; 45: 1458-1467.
6. Kapan M, Kapan S, Pekmezci S, et al. Sacrococcygeal pilonidal sinus disease with Limberg flap repair. *Tech Coloproctol* 2002; 6: 27-32.
7. Arumugam P, Chandrasekaran T, Morgan A, et al. The rhomboid flap for pilonidal disease. *Colorectal Dis* 2003; 5: 218-221.
8. Mahdy T. Surgical treatment of the pilonidal disease: primary closure or flap reconstruction after excision. *Dis Colon Rectum* 2008; 51: 1816-1822.
9. Cihan A, Ucan B, Comert M, et al. Superiority of asymmetric modified limberg flap for surgical treatment of pilonidal disease. *Dis Colon Rectum* 2006; 49: 244-249.
10. Chintapatla S, Safarani N, Kumar S. Sacrococcygeal pilonidal sinus: historical review, pathological insight and surgical options. *Tech Coloproctol* 2003; 7: 3-8.
11. Branagan G, Thompson M, Senapati A. Cleft closure for the treatment of unhealed perineal sinus. *Colorectal Dis* 2006, 8, 314-317.
12. Cripps N, Evans J, Nordon I, et al. Sacrococcygeal pilonidal sinus disease. *Colorectal Dis.* 2009; 11: 105-106.
13. Manterola C, Barroso M, Araya J, et al. Pilonidal disease: 25 cases treated by the Dufourmentel technique. *Dis Colon Rectum* 1991; 34: 649-652.
14. Jeffery M, Billingham N, Billingham R. Pilonidal Disease and Hidradenitis Suppurativa. In: Wolff B, Fleshman J, Beck D, et al, editors. *The ASCRS Textbook of Colon and Rectal Surgery*. 1st ed. New York: Springer; 2007. p. 228-239.
15. Efthimiadis C, Kosmidis C, Anthimidis G, et al. Barber's hair sinus in a female hairdresser: uncommon manifestation of an occupational disease: a case report. *Cases J* 2008 6; 1: 214.
16. Golladay E. Outpatient adolescent surgical problems. *Adolesc Med Clin* 2004; 15: 503-520.
17. Lukish J, Kindelan T, Marmon L, et al. Laser epilation is a safe and effective therapy for teenagers with pilonidal disease. *J Pediatr Surg* 2009; 44: 282-285.
18. Kaymakcioglu N, Yagci G, Simsek A, et al. Treatment of pilonidal sinus by phenol application and factors affecting the recurrence. *Tech Coloproctol* 2005; 9: 21-24.
19. Rao A. Cutting seton for pilonidal disease: a new approach. *Tech Coloproctol* 2006;10:242-244.
20. Gage A, Dutta P. Cryosurgery for pilonidal disease. *Am J Surg* 1977; 133: 249-254.
21. Aldean I, Shankar P, Mathew J, et al. Simple excision and primary closure of pilonidal sinus: a simple modification of conventional technique with excellent results. *Colorectal Dis* 2005; 7: 81-85.
22. Akinci O, Coskun A, Uzunkoy A. Simple and Effective Surgical Treatment of pilonidal sinus, asymmetric excision and primary closure using suction drain and subcuticular skin closure. *Dis Colon Rectum* 2000; 43: 701-707.
23. Oncel M, Kurt N, Kement M. Excision and marsupialization versus sinus excision for the treatment of limited chronic pilonidal disease: a prospective, randomized trial. *Tech Coloproctol* 2002; 6: 165-169.
24. Lynch J, Laing A, Regan P. Vacuum-assisted closure therapy: a new treatment option for

- recurrent pilonidal sinus disease. Report of three cases. *Dis Colon Rectum* 2004; 47: 929–932.
25. Gupta P. Radiofrequency Incision and Lay Open Technique of Pilonidal Sinus Clinical Practice Paper on Modified Technique. *Kobe J Med Sci* 2003; 49:75–82.
26. Bascom J, Bascom T. Failed pilonidal surgery: new paradigm and new operations leading to cure. *Arch Surg* 2002; 137: 1146–1151.
27. Berkem H, Topaloglu S, Ozel H, et al. V–Y advancement flap closures for complicated pilonidal sinus disease. *Int J Colorectal Dis* 2005; 20: 343–348.
28. Arumugam P, Chandrasekaran T, Morgan A, et al. The rhomboid flap for pilonidal disease. *Colorectal Disease* 2003; 5: 218–221.
29. Guyuron B, Dinner M, Dowden R. Excision and grafting in treatment of recurrent pilonidal sinus disease. *Surg Gynecol Obstet* 1983; 156: 201–204.
30. Galala K, Salam I, Sim A, et al. Treatment of pilonidal sinus by primary closure with a transposed rhomboid flap compared with deep suturing: a prospective randomized clinical trial. *Eur J Surg* 1999; 165: 468–472.
31. Edwards M. Pilonidal sinus. A 5 year appraisal of the Millar- Lord treatment. *Br J Surg* 1977; 64:867–868.
32. Patel H, Lee M, Bloom I, et al. Prolonged delay in healing after surgical treatment of pilonidal sinus is avoidable. *Colorectal Dis* 1999; 1: 107–110.
33. Daphan C, Tekelioglu H, Sayilgan C. Limberg Flap Repair for Pilonidal Sinus Disease. *Dis Colon Rectum* 2004; 47: 233–237.
34. Topgul K, O' zdemir E, Kilic K, et al. Long-Term Results of Limberg Flap Procedure for Treatment. *J The Royal Medical Services* 2010;17(4).
35. Testini M, Piccinni G, Miniello S, et al. Treatment of chronic pilonidal sinus with local anaesthesia: arandomized trial of closed compared with open technique. *Colorectal Dis* 2001; 3: 427–430.
36. Khatri V, Espinosa M, Amin A. Management of recurrent pilonidal sinus by simple V-Y fasciocutaneous flap. *Dis Colon Rectum* 1994; 37:1232–1235.

Address for Corresponding Author:**Dr. Zulfiqar Ali Shahid.**

Assistant Professor General Surgery

Surgical Unit III

Nishtar Hospital, Multan.

zulfiqar.as@hotmail.com