

# Findings of Macroscopic and Microscopic Examination of Infants in Live or Stillbirth

Nadia Aslam<sup>1</sup>, Abid Hussain<sup>2</sup>, Ishrat Bibi<sup>1</sup>, Aisha Rasheed<sup>1</sup> and Abdul Aziz Shaikh<sup>2</sup>

## ABSTRACT

**Objective:** To ascertain whether lung examination could provide sufficient pathological insight to distinguish between stillbirth and live birth in infants.

**Study Design:** A comparative observational study

**Place and Duration of Study:** This study was conducted at the Liaquat University Hospital, Hyderabad and department of Forensic Medicine & Toxicology, LUMHS, from January 2023 to June 2024.

**Methods:** All cases were included from the hospital's maternity and pathology departments. During the autopsy, the lungs were examined for external features such as color, consistency, and presence of any anomalies. The lungs were weighed and measured. Each lung was then sectioned, and the internal structure was evaluated for any macroscopic lesions or abnormalities.

**Results:** There were 34.5% cases' lungs had filled by thoracic cavity, 33.8% cases had filled by thoracic partial cavity, 16.2% had without thoracic cavity, whereas 15.5% cases had no information about macroscopically appearance of lungs in the thoracic cavity. Histological results were uniform in 47.9% cases, semi-collapsed in 44.4% cases and collapsed in 7.7% cases.

**Conclusion:** Histologically, the manner of death could not be determined alone. Thus, careful macroscopic and microscopic lung assessments, along with case history and medical record reviews, are advised. Multiple findings were considered to determine stillbirth or live birth.

**Key Words:** Autopsy, Stillbirth, Infant, Lung, Live birth

**Citation of article:** Aslam N, Hussain A, Bibi I, Rasheed A, Shaikh AZ. Findings of Macroscopic and Microscopic Examination of Infants in Live or Stillbirth. Med Forum 2024;35(11): 182-185.doi:10.60110/medforum.351139.

## INTRODUCTION

The bodies of newborns are often disposed of in rivers, rubbish dumps, drains, and other similar places. In rural areas, many births occur at home without medical assistance<sup>1</sup>. If an infant is found dead, the public prosecutor sends the body to an autopsy center<sup>2</sup>. In many cases parents claim that their child was born dead due to medical malpractice or infanticide<sup>3</sup>.

In these cases determination of life is important and impacts subsequent criminal proceedings<sup>4</sup>. Investigating whether an infant was born alive or stillborn is crucial in relation to both criminal law and civil law<sup>5</sup>.

<sup>1</sup>. Department of Forensic Medicine & Toxicology / Pathology<sup>2</sup>, Liaquat University of Medical & Health Sciences, Jamshoro, Sindh, Pakistan.

Correspondence: Dr. Nadia Aslam, Lecturer of Forensic Medicine & Toxicology, Liaquat University of Medical & Health Sciences, Jamshoro, Sindh, Pakistan  
Contact No: 0335 2762814  
Email: drnadiaaslam77@gmail.com

Received: July, 2024

Reviewed: August-September, 2024

Accepted: October, 2024

In various countries civil law mandates that in case an infant was born alive it should be entitled for all civil rights from the fertilization time. Furthermore, contract law mentioned that healthy birth takes over all rights of fetus<sup>6</sup>.

Determination of live birth is important for autopsy and it is an important aspect especially when death is expected to be unusual and unexpected. This procedure requires detailed evaluation of family medical history, clinical data, and place and scene of death<sup>7</sup>. Furthermore, determination of live or still birth is essential for accurate postmortem examination. Examination may include organ weighing, inspection of the physical body, and completion of both microscopic and macroscopic lung examination<sup>8</sup>. Hydrostatic test was also performed for assessment of stomach contents and umbilical cord. Medico-legal investigations of infant autopsies also naturally include considerations of congenital anomalies, natural diseases, birth injuries and trauma that might have contributed to the infant's death<sup>9</sup>.

In newly born infants, whether stillborn, the lung's condition holds specific forensic significance<sup>10</sup>. Critical evaluation of both macroscopic and histological examinations can be instrumental in resolving the case. Beyond histopathological analysis, the macroscopic border features, texture, and appearance of the lungs, as

well as how well they fill the chest cavity, are valuable parameters for diagnosing whether the infant was born still or alive<sup>11</sup>.

As per best of our knowledge no previous study was conducted on the Pakistani population, findings of this study will help medical and forensic pathology training programs incorporate these findings to educate students and professionals on the significance of lung examination in determining live birth versus stillbirth.

## METHODS

This study was designed as a comparative observational analysis conducted at Liaquat University Hospital, Hyderabad and Department of Forensic Medicine & Toxicology, LUMHS Jamshoro spanned a period of 18 months, from January 2023 to June 2024, and included cases from the hospital's maternity and pathology departments. Approval was obtained from the hospital ethics board.

Study sample consisted of stillborn or live born infants, undergone post-mortem examination within twenty four hours delivery. Infants with time between delivery and post-mortem above 24 hours, having multiple congenital anomalies not related to lung disease were excluded. Clinical data including gestational age, maternal history, and delivery mode were recorded. Data collection was started after consent.

During performing autopsy, color, features of lungs (external and internal) presence of anomaly and consistency were examined. Lungs were measured and weighed, and lungs sectioned for internal structure and macroscopic examination was performed for any type abnormality. Sampling of various lung regions was taken and preserved in formalin 10% solution. Histological processing was done step wise which include dehydration, embedding paraffin, sectioning (4-5 microns), hematoxylin and eosin staining. Few extra stains like acid-schiff and Masson's trichrome were used in specific pathologies measurement.

A team of expert pathologists examined the slides under light microscope for hyaline membrane, alveolar development, signs of intra alveolar hemorrhage and inflammatory cell infiltration. All findings were categorized and documented on histopathological criteria.

The collected data were analyzed using descriptive statistics. Comparative analysis was performed to identify significant differences between live-born and stillborn infants. Statistical tests (chi square and t test), were used to determine the significance of observed differences.

## RESULTS

In this study, 52 (24.2%) were live births, 90 (41.9%) were still births and 73 (34.0%) cases had no information/conclusion about that these were live or still birth due to purification of body. There were 81 (57.0%) males and 60 (42.3) females, whereas one case (0.7%) had no information about gender due to advance purification. No association was found between gender and live & still birth, ( $p=0.747$ ). There were 64 (45.1%) cases that had death scene without any eyewitness. No association was found between death scene without eyewitness and live & still birth, ( $p=0.615$ ). There were 62 (43.7%) cases that had maturity. No association was found between maturity and live & still birth, ( $p=0.193$ ). It was found that 105 (73.9%) cases had normal weight whereas 37 (26.1%) cases had small for gestational age. No association was found between infant weight and live & still birth, ( $p=0.827$ ). Only three cases (2.1%) had congenital abnormality. No association was found between congenital abnormality and live & still birth, ( $p=0.275$ ). Further, only two cases (1.4%) had found umbilical cord. No association was found between umbilical cord and live & still birth, ( $p=0.061$ ). There were 49 (34.5%) cases' lungs had filled by thoracic cavity, 48 (33.8%) cases had filled by thoracic partial cavity, 23 (16.2%) had without thoracic cavity, whereas 22 (15.5%) cases had no information. No association was found between lung complications and live & still birth, ( $p=0.664$ ). Hydrostatic test had shown sinking in 83 (58.5%) cases, flotation in 48 (33.8%) cases and partially flotation in 11 (7.7%) cases. No association was found between hydrostatic test and live & still birth, ( $p=0.662$ ). (Table. I).

Histological results were uniform in 68 (47.9%) cases, semi-collapsed in 63 (44.4%) cases and collapsed in 11 (7.7%) cases. (Figure. I).

**Table No. 1: Association of live and stillbirth with clinical outcomes**

Variable	Live birth 52 (24.2%)	Still birth 90 (41.9%)	Total	Test of Sig.
Sex				
Male	30 (56.8)	51 (56.7)	81 (57.0)	$\chi^2=0.584, p=0.747$
Female	22 (43.2)	38 (42.2)	60 (42.3)	
Death scene without any eyewitness				
Yes	22 (42.3)	42 (46.7)	64 (45.1)	$\chi^2=0.253, p=0.615$
No	30 (57.7)	48 (53.3)	78 (54.9)	
Maturity				
Yes	19 (36.5)	43 (47.8)	62 (43.7)	$\chi^2=1.69, p=0.193$

No	33 (63.5)	47 (52.2)	80 (56.3)	
Infant weight				
Normal	39 (75.0)	66 (73.3)	105 (73.9)	$\chi^2=0.048, p=0.827$
Small for gestational age	13 (25.0)	24 (26.7)	37 (26.1)	
Congenital abnormality				
Yes	2 (3.8)	1 (1.1)	3 (2.1)	$\chi^2=1.92, p=0.275$
No	50 (96.2)	89 (98.9)	139 (97.9)	
Umbilical cord				
Yes	2 (3.8)	0 (0.0)	2 (1.4)	$\chi^2=3.51, p=0.061$
No	50 (96.2)	90 (0.0)	140 (98.6)	
Lung complications				
Thoracic cavity	15 (28.8)	34 (37.8)	49 (34.5)	$\chi^2=1.58, p=0.664$
Thoracic partial cavity	18 (34.6)	30 (33.3)	48 (33.8)	
Without thoracic cavity	9 (17.3)	14 (15.6)	23 (16.2)	
No information	10 (19.2)	12 (13.3)	22 (15.5)	
Hydrostatic test				
Sinking	33 (63.5)	50 (55.6)	83 (58.5)	$\chi^2=0.949, p=0.622$
Flotation	15 (28.8)	33 (36.7)	48 (33.8)	
Partially flotation	4 (7.7)	7 (7.8)	11 (7.7)	
Histological results				
Uniform	24 (46.2)	44 (48.9)	68 (47.9)	$\chi^2=2.25, p=0.325$
Semi-collapsed	26 (50.0)	37 (41.1)	63 (44.4)	
Collapsed	2 (3.8)	9 (10.0)	11 (7.7)	

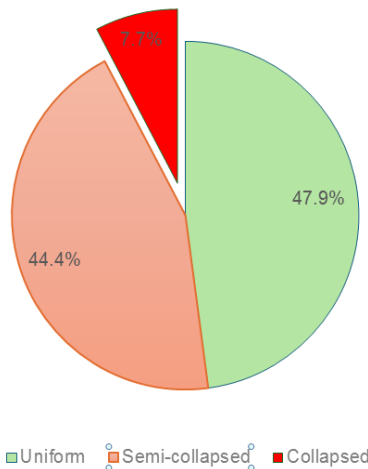


Figure No. 1: Histological findings

**DISCUSSION**

This study emphasizes the superior reliability of registered medical data over oral accounts in determining whether an abandoned infant was born alive, crucial for the medico-legal investigation. Contrary to mothers' claims, especially regarding stillbirth, their statements were considered less dependable compared to other witnesses, aligning with previous findings by Knight and Saukko et al<sup>12</sup>. and reiterated by Marchetti et al<sup>13</sup>. In this study lungs can be classified macroscopically as respired (pink, soft, round edges covering the heart) or unrespired (dark red, solid, sharp edges, not covering the heart). Unrespired infant lungs resemble the liver and lack crepitation without artificial respiration or putrefaction. Partial aeration may occur during birth

and resuscitation. In a study Stocker et al<sup>14</sup> recommend gastrointestinal examination and radiological examination of lungs before autopsy if no putrefaction or artificial respiration is present.

In our study, we found no significant correlation between the hydrostatic test results and macroscopic lung findings in cases involving live or stillbirth, despite considering clinical data. Keeling et al<sup>15</sup> study highlighted that the hydrostatic test might yield false-negative results in live-born infants experiencing premature birth, hyaline membrane disease, or exposure to high levels of stress or 100% oxygen respiration. Breeze et al<sup>16</sup> study has highlighted that infection or edema in the lungs of live-born infants can lead to false-negative results, indicating that the hydrostatic test is not a reliable diagnostic tool for distinguishing between live births and stillbirths.

The study found that only three cases (2.1%) out of the total had congenital abnormalities, suggesting a minimal association between congenital abnormalities and both live and stillbirths (p=0.275). deRoux et al<sup>17</sup> emphasized that maceration serves as a conclusive indicator of stillbirth.

In this study, no significant association was found between stillbirth and umbilical cord examination, despite the certainty of live birth being established by evaluating umbilical cord division area for inflammatory reaction. Ong et al<sup>18</sup> emphasized the importance of histopathological inspection involving the umbilical cord, umbilical skin, and intra-abdominal vessels along the vertical axis for comprehensive evaluation. In another study researcher highlight that histologically, signs of inflammation surrounding the umbilical cord can become evident remarkably soon after birth, with observations showing these

inflammatory changes as early as 2 to 3 hours postpartum.

In a study, it was found that 34.5% of cases had lungs filled by the thoracic cavity, while 33.8% had lungs filled by the thoracic partial cavity. Additionally, 16.2% of cases did not have the thoracic cavity filled by the lungs, and 15.5% had no information available regarding the lung's appearance in the thoracic cavity. In a similar study by Turan et al<sup>20</sup> it was reported that in 26.37% of cases, the lungs covered the heart anterior surface and thoracic cavity, whereas in 32.7% of cases, the lungs did not fill the thoracic cavity and were positioned at the back side of it.

## CONCLUSION

Extent of maturation, infant weight, and findings of hydrostatic tests for lungs were useless for determining stillbirth or live birth. However, macroscopic lung examination was valuable. Microscopically, alveolar aeration indicated live birth without putrefaction and artificial respiration. Histologically, the manner of death could not be determined alone. Thus, careful macroscopic and microscopic lung assessments, along with case history and medical record reviews, are advised. Multiple findings were considered to determine stillbirth or live birth.

### Author's Contribution:

Concept & Design or acquisition of analysis or interpretation of data:	Nadia Aslam, Abid Hussain, Ishrat Bibi
Drafting or Revising Critically:	Aisha Rasheed, Abdul Aziz Shaikh
Final Approval of version:	All the above authors
Agreement to accountable for all aspects of work:	All the above authors

**Conflict of Interest:** The study has no conflict of interest to declare by any author.

**Source of Funding:** None

**Ethical Approval:** LUMHS/REC/95 dated 01.01.2023

## REFERENCES

- Parikesit RA, Novita N, Usman HA. Pathological findings of the Lung at neonatal autopsy in Dr. Hasan Sadikin General hospital Bandung period 2016-2019. *Althea Med J* 2021;8(3):149-54.
- Kulkarni AD, Palaniappan N, Evans MJ. Placental pathology and stillbirth: a review of the literature and guidelines for the less experienced. *J Fetal Med* 2017;4(04):177-85.
- Lee H, Lee S, Cha JG, Baek T, Yang KM. Postmortem Computed Tomography and Computed Tomography Angiography: Cardiothoracic Imaging Applications in Forensic Medicine. *J Thorac Imaging* 2019;34(5):286-298.
- Mila H, Guerard C, Raymond-Letron I. Guidelines for postmortem examination of newborn dogs. *Anim Health Res Rev* 2021;22(2):109-19.
- Pinar H, Goldenberg RL, Koch MA, Heim-Hall J, Hawkins HK, Shehata B, et al. Placental findings in singleton stillbirths. *Obstetr Gynecol* 2014;123(2 PART 1):325-36.
- Ducloyer M, David A, Dautreme B, Tournel G, Vincent F, Clement R, et al. Pictorial review of the postmortem computed tomography in neonaticide cases. *Int J Legal Med* 2021;135(6):2395-2408.
- Ravishankar S, Migliori A, Struminsky J, Has P, Sung CJ, He M. Placental findings in fetomaternal hemorrhage in livebirth and stillbirth. *Pathol Res Pract* 2017;213(4):301-4.
- Capas-Peneda S, Munhoz Morello G, Lamas S, S Olsson IA, Gilbert C. Necropsy protocol for newborn mice. *Lab Anim* 2021;55(4):358-62.
- Phillips B, Ong BB. "Was the infant born alive?" A review of postmortem techniques used to determine live birth in cases of suspected neonaticide. *Acad Forens Pathol* 2018;8(4):874-93.
- Lou SK, Keating S, Kolomietz E, Shannon P. Diagnostic utility of pathological investigations in late gestation stillbirth: a cohort study. *Pediatr Dev Pathol* 2020;23(2):96-106.
- Neri M, D'Errico S, Fiore C, Pomara C, Rabozzi R, Riezzo I, et al. Stillborn or liveborn? Comparing umbilical cord immunohistochemical expression of vitality markers (tryptase,  $\alpha$ 1-antichymotrypsin and CD68) by quantitative analysis and confocal laser scanning microscopy. *Pathol Res Pract* 2009;205(8):534-41.
- Saukko P, Knight B. Infanticide and stillbirth. *Knights Forensic Pathol* 2004;3:439-50.
- Marchetti D, Belviso M, Marino M, Gaudio R. Evaluation of the placenta in a stillborn fetus to estimate the time of death. *Am J Forensic Med Pathol* 2007;28(1):38-43.
- Stocker JT, Nicholson AG, Colby TV, Burke AP, Frazier AA, Virmani R, et al. Symposium 24: non-neoplastic lung disease. *Histopathol* 2002;41:424.
- Keeling JW. Fetal and perinatal death. *Pediatric Forensic Med Pathol* 2009:180-97.
- Breeze AC, Jessop FA, Whitehead AL, Set PA, Berman L, Hackett GA, et al. Feasibility of percutaneous organ biopsy as part of a minimally invasive perinatal autopsy. *Virchows Arch* 2008; 452:201-7.
- DeRoux SJ, Prendergast NC. Pulmonary interstitial emphysema in live birth determination: radiographic and gross pathologic features. *J Forensic Sci* 2006;51(1):134-6.
- Ong BB, Green M. Infanticide in Malaysia: two case reports and a review of literature. *Am J Forensic Med Pathol* 2003;24(1):64-9.
- Hausmann R, Bock H, Biermann T, Betz P. Influence of lung fixation technique on the state of alveolar expansion—a histomorphometrical study. *Legal Med* 2004;6(1):61-5.
- Turan Yurtsever NU. Macroscopic and microscopic findings of infant lung in case of live or still birth. *Scientific Scientific Res Essays* 2013;8(21):870-74.