

An Audit of Radiological Imaging in Physical Injuries and Their Medicolegal Patterns at A Tertiary Care Hospital of Sindh

Radiological
Imaging of
Injuries and
Their
Medicolegal

Ikram Ahmed Tunio¹, Muhammad Qasim Memon² and Waheed Ali Nahyoon²

ABSTRACT

Objective: The present study was conducted to report the patterns of radiological imaging of physical injuries and its medicolegal implications presenting at a tertiary care hospital of Sindh.

Study Design: Observational study

Place and Duration of Study: This study was conducted at the Department of Radiology, Chandka Medical College Hospital Larkana from August 2014 to July 2016.

Materials and Methods: Record of 5130 patients was screened of which only 987 fulfilled the inclusion criteria. Plain X-rays, CT scan, ultrasound and magnetic resonance imaging (MRI) records were checked for the findings of bony injury, body parts imaged, cause and nature of physical injury. Microsoft excels and Statistix 8.1 version (USA) was used for the data analysis (P-value ≤ 0.05).

Results: Mean \pm SD age was noted as 34 ± 15.9 years. Of 987, 880 (89.15%) were male and 107 (10.84%) were female ($p=0.0001$). Plain X-rays were performed in 99.81%, Sonography in (24.11%), CT scans in (33.43%) and MRI in (13.8%) ($p=0.0001$). Fractures of limb bones, skull, chest cage and pelvic bones were noted. Motor bicycle (44.07%) was most common cause of physical injury followed by motor vehicle (25.83%) and fire arm injuries (8.71%). Medicolegal patterns reveal 6% were accidental, 2% homicidal and remaining were non- medicolegal cases.

Conclusion: Common cause of physical injuries was the motor cycle use and radiological imaging was helpful in rapid diagnosis in particular of bony fractures for early medical therapy. CT scan and MRI are necessary for head injuries cases.

Key Words: Physical injuries, X-rays, CT scan, MRI, Medicolegal Patterns

Citation of articles: Tunio IA, Memon MQ, Nahyoon WA. An Audit of Radiological Imaging in Physical Injuries and Their Medicolegal Patterns at A Tertiary Care Hospital of Sindh. Med Forum 2017;28(7):25-29.

INTRODUCTION

Physical injuries are a common problem of modern life and radiological examination of affected body part is essential for necessary therapeutic regimens to be instituted. Radiological examination of affected body part is an essential clinical tool at the emergency departments.^{1,2} Physical injuries have multiplied due to motor vehicles availability and non-abiding of traffic rules resulting in road traffic accidents (RTA). This problem is universal; occurrence has increased throughout the World. Physical injuries usually involve one or more bony parts of body. Bony injuries are

problematic because of surgical management, disability, long duration for healing, and loss of work and financial burden.^{1,2} In Pakistan, the urbanization is on rise, similarly the motor vehicle use, law and order situations, violence, injustice while public intolerance is on decline. Fire arms and social violence are major problems of urban life. Modernization and industrialization have opened new chapters of public problems which are not handled properly. Availability of rapid and true justice is a dream which has become a nightmare and people are ready to fight on trivial problems.¹ Motor vehicle injuries occupy top followed by fire arm injuries. Physical injury tolls for a large number of deaths, disability, and financial problems in particular for the deprived families of society.² A previous study reported mortality and morbidity in physical injuries due to RTA resulting in the functional disability.³ Physical injury may be isolated affecting only a single body part or may be generalized. RTAs usually cause serious multiple body injuries, damaging both soft and bony body parts. RTA, bomb blasts, sports and assaults usually result in death or severe physical injuries necessitating urgent surgical and medical measures to save the lives. World directory shows the RTA rank 9th position as cause of physical

¹. Department of Forensic Medicine and Toxicology, Shaheed Mohtarma Benazir Bhutto Medical University (SMBBMU), Larkana.

². Department of Forensic Medicine and Toxicology, Liaquat University of Medical and Health Sciences, Jamshoro.

Correspondence: Dr. Waheed Ali Nahyoon, Assoc. Prof. Department of Forensic Medicine and Toxicology, Liaquat University of Medical and Health Sciences, Jamshoro.

Contact No: 0300-3316294

Email: dr_waheednahyoon@yahoo.com

Received: May 22, 2017;

Accepted: June 27, 2017

injuries, which is projected to 3rd position by the year 2020.⁴ This needs the health providing institutes should be prepared in advance for handling the ever rising problem of physical injuries.^{5,6} Radiological imaging plays primary role in the diagnosis and management of physical injuries. The victims need the imaging studies urgently to initiate the surgical and medical intervention in time and in proper direction. A report shows 1.2 million people die because of physical injuries.⁷ The rising death toll because of physical injuries is a risk for the low- and middle-income developing countries.^{7,8} Motor bicycles and motor vehicles have become a popular means of transport in Pakistan; both for personal and commercial purpose.⁹ This has multiplied the physical injuries inflicted during RTAs which are common due to non- implementation of driving laws. Unfortunately, the majority of public is ignorant and don't abide by the traffic laws.^{10,11} The present clinical audit is a retrospective report which is being reported on the role of radiological imaging in the management of physical injuries presenting at our tertiary care hospital. The present report will highlight the problem in the greater interest of public to abide by the traffic laws and the traffic department to be more conscious and vigilant at least to minimize the road traffic accidents, physical injuries, economical loss and mortality.

MATERIALS AND METHODS

The present observational study was conducted at the Department of Radiology, Chandka medical college hospital Larkana sindh between August 2014 and July 2016. Subjects of physical injuries presenting at the emergency unit of hospital are referred to the Department of Radiology. X-rays and computerized tomography scanning are frequent investigations for the hard and soft tissue injuries. Our hospital provides best radiological imaging services at affordable charges. Radiology department is one of the busiest departments having working collaboration with emergency department round the clock working 24 hours. Patients of >20 years of age, both genders, and not critically ill were included in the study protocol. Patients with serious physical injuries, admitted in the intensive care units were excluded. Non willing subjects were also excluded. Physical injury was defined as a body injury occurred by motor bike, motor car, motor cycle, etc. Victim was defined as subjects who got body injury as a rider, innocent road bystander, a passenger and or a pedestrian. Permission was taken from the institutional ethical committee before conducting the research. A proforma was designed to collect the patient's biodata; physical injuries, radiological imaging and findings were noted. Bony injuries, imagined bony parts, physical findings, causes and medicolegal nature of physical injuries were collected and saved carefully in the proforma. Data of 5130 patients was collected; of

which only 987 fulfilled the inclusion criteria and included the study protocol. Plain X-rays, CT scan, ultrasound and magnetic resonance imaging (MRI) records were checked for the findings of bony injury, body parts imagined, cause and nature of physical injury, bullets, foreign bodies and bony fractures. Consent was necessary in certain cases of medicolegal nature only. Confidentiality of data was maintained by keeping the proforma secured. Only concerned researcher could approach the record of patients. The data was typed on the Microsoft excel sheet, was copied to the Statistix 8.1 version (USA). Continuous data was analyzed by the Student's t-test and results were presented as mean \pm SD. Cross tabulation was performed for the categorical variables using Chi square test and results were presented as frequency and percentage. Graphs were generated by the Microsoft excel sheet. Statistical significance was considered significant at confidence interval of 95% ($P \leq 0.05$).

RESULTS

Age, calculated as mean \pm SD, was noted as 34 ± 15.9 years. 46.4% of study subjects belonged to the 2nd decade of life followed by 3rd decade as second most common in 20.7%. ≥ 60 years was least age group noted in 1.2% ($p=0.0001$) (table 1). Of 987, 880 (89.15%) were male and 107 (10.84%) were female ($p=0.0001$) (table 1 and graph 1). Majority of subjects belonged to lower social class (67.5%), urban population (85.41%) and uneducated (69.30%) ($p=0.001$, $p=0.0013$ and $p=0.0012$ respectively) as shown in table 1.

Table No. 1: Age distribution of study subjects (n=987)

	No	%	P-value
Age			
10- 19.9 years	458	46.4	0.0001
20- 29.9 years	207	20.7	
30- 39.9 years	123	12.46	
40- 49.9 years	119	12.05	
50-59.9 years	61	6.18	
≥ 60 years	19	1.92	
Male	880	89.15	0.0001
Female	107	10.84	
Urban	843	85.41	0.0001
Rural	144	14.58	
Lower social class	667	67.57	0.0013
Middle social class	142	14.38	
Upper social class	178	18.03	
Educated	303	30.69	0.0012
Uneducated	684	69.30	

Frequency of radiological examination of body parts and radiological imaging category are shown in table 2. Most common imagined body parts were the limbs,

followed by head, chest and pelvic bones. Plain X-rays were performed in 99.81%, Sonography in (24.11%), CT scans in (33.43%) and MRI in (13.8%) ($p=0.0001$) as shown in table 2. Frequency of bony parts x-rayed, causes and medicolegal patterns of physical injuries are shown in table 3, 4 and 5 respectively. Fractures of limb bones, skull, chest cage and pelvic bones were noted. Motor bicycle (44.07%) was most common cause of physical injury followed by motor vehicle (25.83%) and fire arm injuries (8.71%). Pedestrians comprised of 12.46% of total cases (table 4 and graph 1). Medicolegal patterns of physical injuries reveals 5.67% were accidental, 2.67% homicidal and non-medicolegal cases were noted as 91.79% as shown in table 5 and graph 2.

Table No.2: Frequency of radiological examination of body parts (n=987)

	No.	%
X-ray body parts		
Upper limbs	213	21.58
Lower limbs	220	22.28
Head	182	18.43
Spine	108	10.94
Chest	112	11.34
Pelvis	122	12.36
Abdomen	30	3.03
Radiological Category		
Plain X-ray	979	99.81
Sonography	238	24.11
CT scanning	330	33.43
MRI scanning	137	13.80

Table No.3: Frequency of bony part X-rays (n=987)

	No	%
Thumb bones	23	2.33
Hand bones	91	9.21
Skull	85	8.61
Pelvic bones	55	5.57
Radius+ Ulna	105	10.63
Clavicle	86	8.71
Wrist bones	40	4.05
Femur	52	5.26
Tibia	193	19.55
Fibula	37	3.74
Chest	85	8.61
Bones of foot	27	2.73
Patella	31	3.14

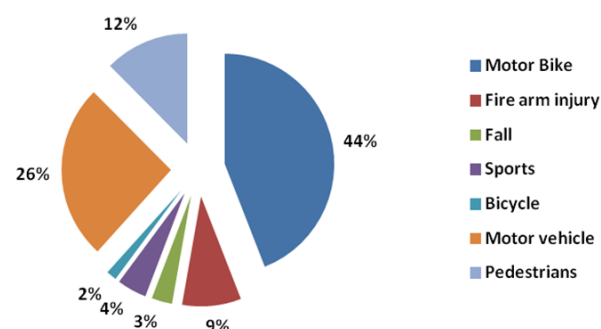
Table No. 4: Causes of Physical injuries (n=987)

	No	%
Motor bicycle	435	44.07
Fire arm injury	86	8.71
Fall	30	3.03
Sports	43	4.35
Bicycle	15	1.51
Motor vehicle	255	25.83

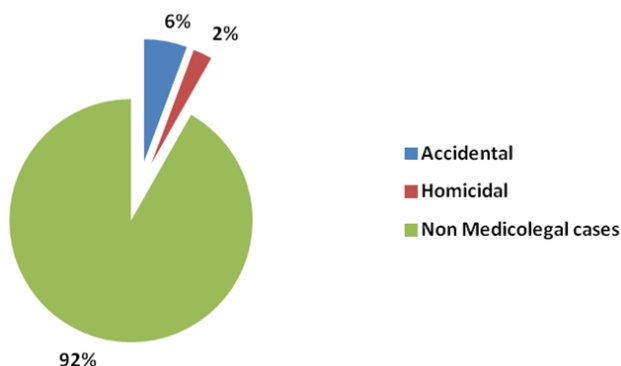
Pedestrians	123	12.46
-------------	-----	-------

Table No.5: Medicolegal Patterns of Physical Injuries (n=987)

	No	%
Accidental	56	5.67
Homicidal	25	2.53
Non Medicolegal cases	906	91.79



Graph No.1: Causes of Physical injuries



Graph No.2: Medicolegal patterns of Physical injuries

DISCUSSION

The present is the first research being reported for the radiological imaging in the diagnosis of physical injuries and its medicolegal implications from our tertiary care hospital. The Physical injuries are on incline because of motor vehicle availability and traffic rules are neglected at all. This has resulted in the morbidity and mortality in the country. The present research highlights the importance of radiological imaging in saving the lives, making a proper diagnosis of soft and bony injuries, and implementation of proper therapeutic measures. This saves the community against the morbidity and mortality. Bony fractures are a cause of physical disability which is a cause of handicap and loss of physical movement of bread earners in the society. Road traffic accidents have topped as a cause of physical injuries due to traffic law disobedience and negligence. Radiological imaging is of prime importance in the physical injuries in daily clinical practice. Many of RTA victims are presenting at the

emergency units of tertiary care hospitals for the treatment purpose. In present study, majority of physical injuries victims were teenagers of second decade of life. The age, calculated as mean \pm SD was noted as 34 ± 15.9 years. This shows a young age being the victims of physical injury. The findings are in agreement with previous studies.¹¹⁻¹³ 46.4% of study subjects belonged to the 2nd decade of life followed by 3rd decade as second most common in 20.7%. ≥ 60 years was least age group noted in 1.2% ($p=0.0001$) (table 1). The findings are in agreement with previous studies.¹¹⁻¹³ Of 987, 880 (89.15%) were male and 107 (10.84%) were female ($p=0.0001$). The male dominance is in keeping with previous studies.^{12,13} This is because our society is male dominated which are involved in outside home activities, running the motor vehicles hence prone to get physical injuries, while the female are usually engaged in the in-house activities. Majority of subjects belonged to lower social class (67.5%), urban population (85.41%) and uneducated (69.30%) ($p=0.001$, $p=0.0013$ and $p=0.0012$ respectively). These findings are supported by previous studies.^{14,15} Most common injured body parts were the limbs, followed by head, chest and pelvic bones. Fractures of limb bones, skull, chest cage and pelvic bones were noted. Pedestrians comprised of 12.46% of total cases. The findings are consistent to the previous studies.^{12,13} Radiological imaging reveals bony fractures of lower limb as most common followed by upper limb bony fractures, head, chest and vertebral column. Our findings are supported by previous studies.¹⁶⁻¹⁹ Plain X-rays were performed in 99.81%, Sonography in (24.11%), CT scans in (33.43%) and MRI in (13.8%) ($p=0.0001$). The findings are in agreement with the previous studies.^{20,21} Bony fractures of limbs, skull, chest, and bony pelvis were the most common noted. Motor bicycle (44.07%) was most common cause of physical injury followed by motor vehicle (25.83%) and fire arm injuries (8.71%). Previous studies^{20,21} had reported similar patterns of physical injuries. Medicolegal patterns of physical injury reveals 5.67% were accidental, 2.67% homicidal and non-medicolegal cases were noted as 91.79%. The findings are consistent to previous studies.^{18,19} Previous reported^{22,23} reported the bony injuries of limbs are most common, the findings support our present study. Limb injuries due to motor bikes was commonest cause of bone fractures is in agreement with previous studies.^{22,23} Our findings of physical injuries are supported by previous study from Nigeria.²⁴ Plain x-rays were the most common radiological investigations noted in present study, this is consistent to previous studies.^{24,25} Our findings of chest, pelvic and spinal injuries are in full agreement with reported studies.²⁶⁻²⁸ CT scans were mostly advised for the head injuries followed by chest and abdominal trauma. Head injuries were common in the motor cyclist which is consistent to previous studies.^{27,28} The

reason is the youngsters avoid helmet and never use it, this cause is frequently reported.^{29,30} The motor cycling is the major cause of physical injuries and radiological imaging is necessary for timely institution of proper medical treatment.

CONCLUSION

The present study shows the motor vehicle injuries as the most common cause of physical injuries and radiological imaging is a par excellence in providing a rapid diagnosis of bony injuries for proper and rapid medical management. Analysis shows most cases are non-medicolegal cases. Accidental and homicidal cases comprised only 6% and 2% respectively. Preventable causes of physical injuries such as using helmet by motor cyclist may decrease the morbidity and mortality.

Author's Contribution:

Concept & Design of Study: Ikram Ahmed Tunio
 Drafting: Mohammad Qasim Memon
 Data Analysis: Waheed Ali Nahyoon
 Revisiting Critically: Mohammad Qasim Memon
 Final Approval of version: Ikram Ahmed Tunio

Conflict of Interest: The study has no conflict of interest to declare by any author.

REFERENCES

1. Saleem S, Haider A, Khan J, Saleem T. Study of medico-legal autopsies due to road traffic accidents. *Gomal J Med Sci* 2015;13:19-22
2. Aduayi OS, Famurewa OC, Adetiloye VA. Radiological imaging of motorcycle-related injuries in a developing country: Experience in a tertiary health facility in the South-Western Nigeria. *J Curr Res Sci Med* 2015;1: 36-40.
3. Hassan Q, Bashir RM, Shah M. Physical trauma: A leading cause of medico-legal cases at DHQ Hospital Abbottabad. *J Ayub Med Coll Abbottabad* 2010; 22:156-8.
4. Adeyemi-Doro HO. Trends in Trauma Care in Nigeria. *Afr J Trauma* 2003; 1: 35 - 38.
5. Chandran A, Hyder AA, Peek-Asac. The Global Burden of Unintentional Injuries and an Agenda for Progress. *Oxford J Med Epi Rev* 2010;32: 110-20.
6. Ahmad T, Abdul Muhammad Z, Humayun Matin B, Tariq Malik A, Quadri S. Calcaneal fractures: an audit of radiological outcome. *J Pak Med Assoc* 2015; 65(11): S-171-S-174.
7. Solagberu BA, Ofoegbu CK, Nasir AA, Ogundipe OK, Adekanye AO, Abdur Rahman LO. Motorcycle injuries in a developing country and the vulnerability of riders, passengers, and pedestrians. *Inj Prev* 2006; 12: 266- 8.
8. Umerani MS, Abbas A, Bakhshi SK, Qasim UM, Sharif S. Evolving brain lesions in the follow-up

- CT scans 12 h after traumatic brain injury. *J Acute Dis* 2016; 5(2): 150–153.
9. Umerani MS, Abbas A, Sharif S. Traumatic brain injuries: experience from a tertiary care centre in Pakistan. *Turk Neurosurg* 2014; 24(1): 19-24.
 10. Chima SA, Aminat FO, Abiodun PO, Nicholas K I, Zaccheus IA, Temitope AO. Plain X-ray findings among chest trauma patients in Lagos. *West Afr J Radiol* 2016;23:16-9
 11. Ekpe EE, Eyo C. Determinants of mortality in chest trauma patients. *Niger J Surg* 2014; 20:30-4.
 12. Figueiredo S, et al. Use of MRI by radiologists and orthopaedic surgeons to detect intra-articular injuries of the knee. *Rev Bras Ortop* 2017;1:1-5.
 13. Timotijevic S, Vukasinovic Z, Bascarevic Z. Correlation of clinical examination, ultrasound sonography, and magnetic resonance imaging findings with arthroscopic findings in relation to acute and chronic lateral meniscus injuries. *J Orthop Sci* 2014;19(1):71–6.19.
 14. Yilgor C, Atay OA, Ergen B, Doral MN. Comparison of magnetic resonance imaging findings with arthroscopic findings in discoid meniscus. *Knee Surg Sports Traumatol Arthrosc* 2014; 22(2):268–73.20.
 15. Sharifah MI, Lee CL, Suraya A, Johan A, Syed AF, Tan SP. Accuracy of MRI in the diagnosis of meniscal tears in patients with chronic ACL tears. *Knee Surg Sports Traumatol Arthrosc* 2015; 23(3):826–30.21.
 16. La Prade RF, Ho CP, James E, Crespo B, LaPrade CM, Matheny LM. Diagnostic accuracy of 3.0 T magnetic resonance imaging for the detection of meniscus posterior root pathology. *Knee Surg Sports Traumatol Arthrosc* 2015; 23(1):152–7.22.
 17. Smith C, McGarvey C, Harb Z, Back D, Houghton R, Davies A, et al. Diagnostic efficacy of 3-T MRI for knee injuries using arthroscopy as a reference standard: a meta-analysis. *AJR Am J Roentgenol* 2016; 207(2):369–77.23.
 18. Umebese PF, Okukpo SU. Motorcycle accidents in a Nigerian University Campus: A one year Study of a pattern of trauma sustained in a University Campus. *Niger J Clin Pract* 2001;10:433- 6.
 19. Solagberu BA, Ofoegbu CK, Nasir AA, Ogundipe OK, Adekanye AO, Abdur Rahman LO. Motorcycle injuries in a developing country and the vulnerability of riders, passengers, and pedestrians. *Inj Prev* 2006; 12:266- 8.
 20. Van Dyck P, Vanhoenacker FM, Lambrecht V, Wouters K, Gielen JL, Dossche L, et al. Prospective comparison of 1.5 and 3.0-T MRI for evaluating the knee menisci and ACL. *J Bone Joint Surg Am* 2013; 95(10):916–24.24.
 21. Babaei Jandaghi A, Mardani-Kivi M, Mirbolook A, Emami-Meybodi MK, Mohammadzadeh S, Farahmand M. Comparison of indirect MR arthrography with conventional MRI in the diagnosis of knee pathologies in patients with knee pain. *Trauma Mon* 2016;21(2):e20718.25.
 22. Oluwadiya KS, Oginni LM, Olasinde AA, Fadiora SO. Motorcycle limb injuries in a developing country. *West Afr J Med* 2004;23:42-7.
 23. Ankarath S, Giannoudis PV, Barlow I, Bellamy MC, Matthews SJ, Smith RM. Injury patterns associated with mortality following motorcycle crashes. *Injury* 2002; 33:473-7.
 24. Shamim S, Razzak JA, Jooma R, Khan U. Initial results of Pakistan's first road traffic injury surveillance project. *Int J Injury Control Safety Promot* 2010; 18:213-7.
 25. Bhatti JA, Ejaz K, Razzak JA, Tunio IA, Sodhar I. Influence of an enforcement campaign on seat-belt and helmet wearing, Karachi Hala highway, Pakistan. *Ann Adv Automot Med* 2011;55:65-70.
 26. Shafi S, Ameer Y, Masood R, Mengal RA, Tariq A. Epidemiological Study of Road Traffic Accident Cases. *Pak J Med Health Sci* 2015;9 (2): 522-25.
 27. Chalya PL, Mabula JB, Ngayomela IH, Kanumba ES, Chandika AB, Giiti G, et al. Motorcycle injuries as an emerging public health problem in Mwanza City, north western Tanzania. *Tanzan J Health Res* 2010;12:214-21.
 28. Eze CU, Abonyi LC, Ohagwu CC, Eze JC. The pattern of plain X-ray findings in bone injuries among motorcycle accident victims in Lagos, Nigeria. *Int Res J Med Med Sci* 2013;1:51- 5.
 29. Dongo AE, Kesieme EB, Eighemherio A, Nwokike O, Esezobor E, Alufohai E. Motorcycle related injuries among rural dwellers in Irrua, Nigeria: Characteristics and Correlates. *Emerg Med Int* 2013; 13:569103.
 30. Ogbeide E, Isara AR. Cranial computed tomography utilization in head trauma in a Southern Nigerian tertiary hospital. *Sahel Med J* 2015; 18:27-30.